

**C**are of pediatric patients is becoming an important segment of avian medicine as legislation and economic factors continue to restrict the importation of wild-caught psittacine birds. Because most birds entering the pet trade come from domestic sources, it is to the advantage of avian practitioners to become knowledgeable in avicultural and pediatric medicine.

Birds may be classified according to their state of maturity at hatching. Precocial birds such as pheasants, ostriches and waterfowl are covered with down and are able to see, walk and feed themselves at hatching. Altricial species such as psittacine birds, song birds and pigeons are helpless at hatch. Most altricial birds are born naked with their eyes closed and depend totally on their parents for food and warmth. Neonates lack a fully competent immune system and are more susceptible to disease than older birds. Because they are helpless, the conditions under which they are maintained, the diet they are fed and the amount of parental care they receive all have a profound influence on their health.

Genetics, incubation and nutrition all affect the early survivability and growth of the chick. A chick with a poor start may develop clinical problems much later in life.

## CHAPTER

# 30

## NEONATOLOGY

Keven Flammer  
Susan L. Clubb

Avian Neonatology: Poultry and Aquarium 1994



## Options for Raising Birds

Chicks can be raised by their parents, by avian foster parents or by humans (hand-raised). Each of these options has particular advantages and disadvantages.<sup>9,18</sup>

### Parent-raising

Allowing the parents to raise their own offspring has some advantages if the parents provide adequate care. It saves the considerable labor associated with hand-feeding, and parent-raised chicks usually develop faster (Figure 30.1). Parent-raised birds may also acquire species-specific behavioral traits that may be lacking in hand-raised chicks. For example, hand-raised Thick-billed Parrot chicks failed to show normal flocking behavior, suggesting that parent-raised chicks may be more desirable for reintroduction programs. Roudybush found that compared to parent-raised birds, hand-raised male cockatiels inseminated females less frequently, and hand-raised females laid more eggs but often failed to lay them in the nest box.<sup>30</sup> This work has not been repeated in other psittacine species. It is known that hand-raising does not prevent normal breeding behavior, and many aviculturists believe that hand-raised chicks are better adapted to captivity and will breed sooner than chicks raised by other means.

There are disadvantages to leaving nestlings with the parents. Captive parents do not always provide optimal care and may traumatize, fail to feed, improperly feed or abandon chicks, especially if there



**FIG 30.1** Allowing parents to raise neonates saves time and would be indicated for any offspring being considered for breeding or reintroduction to the wild. Hand-raised birds may make better pets (courtesy of Deanna Shafar).

are disturbances in the aviary (Color 30.9). The chicks may also be exposed to diseases carried by the parents. Chicks that are parent-raised beyond the pin-feather stage are also more difficult to tame and are less suitable as pets. Many aviculturists elect to hand-raise the larger, more expensive psittacine birds. Parent-raising is most often used with small, highly productive species such as cockatiels, lovebirds and budgerigars where the cost of hand-raising is difficult to recover upon sale of the bird.

### Fostering

Fostering refers to moving eggs or babies from one nest to another. Some bird species (eg, Society Finches and canaries) make excellent foster parents and will feed neonates from species other than their own. Fostering is necessary when chicks are from neglectful or abusive parents or when there are large differences in the sizes of the chicks or between the times the eggs hatch. Fostering may also be used to increase production by removing eggs from a productive pair, which will stimulate them to lay more eggs. In most cases it is desirable to foster eggs rather than chicks, and the foster nest should have eggs or chicks of a similar age. Society Finches may foster chicks of any age. Fostering may spread disease, and the medical histories of both sets of parents should be established before considering cross-fostering.

### Hand-raising

Aviculturists may hand-raise birds for the following reasons:

- To produce a tame bird that will socialize with people.
- To increase production by encouraging a pair of birds to lay additional clutches.
- To raise offspring hatched from artificially incubated eggs.
- To save sick or abandoned offspring.
- To reduce the burden of parental care on a compromised parent.
- To prevent or reduce the transmission of disease from the parents to the neonate.

The disadvantages of hand-raising include the intensive labor required to feed birds and the threat of disease outbreaks that can occur when multiple nestlings from different pairs are concentrated in a nursery. Hand-raised birds seldom gain weight as quickly in the initial week of growth as parent-raised chicks; however, they usually compensate later and wear a normal weight.



### Problems Associated with Parent-raised Birds

Nestling birds are most likely to have medical problems during the first week of life, at fledging and at weaning. Monitoring the condition of parent-raised offspring in the nest box can be difficult. Semi-domesticated species such as budgerigars, cockatiels, finches and lovebirds may tolerate repeated evaluation and handling of their offspring. Larger psittacine birds are usually protective of the nest box, and the aviculturist should establish a routine of examining the nest box daily to condition the birds to this procedure. Nest boxes should be constructed with a small door that can be used for viewing the chicks and examining the eggs. A fiberoptic light and mirror may be helpful.

Chicks receiving adequate parental care will have food in their crops and yellowish-pink skin (Color 30.3). Chicks that have empty crops, act listless and are cool to the touch are receiving inadequate care and should receive immediate attention. These chicks may be hypothermic, hypoglycemic, dehydrated or have bacterial or yeast infections. The solution to many of the problems associated with parent-raised neonates is to remove them for hand-raising. Care of the critically ill neonate is described in the section on hand-raising.

#### Parental Problems

Parenting is a learned process and captive birds do not always make ideal parents, especially with the first few clutches. Parents may eat, traumatize or abandon the eggs or the chicks. Some parents never learn to provide adequate care; others may learn to provide improved care with subsequent clutches. Disturbances in the aviary will increase parental problems. Most psittacine birds lay eggs every two to three days and start incubation when the first egg is laid. Highly productive species such as cockatiels may lay an additional clutch before fledging chicks from the previous lay. These adults may remove the feathers from the chicks in an attempt to encourage them to leave the nest.

#### Nestling Problems

A healthy nestling will interact with the parents and elicit feeding activity by displaying a food-begging behavior. Any factor that decreases the vigor of the chicks (disease, cold,

competition) can decrease their chances of being properly fed. Often the older and more vigorous chicks will compete most efficiently for food and parental attention, causing younger chicks to be neglected and undernourished.

#### Environmental Problems

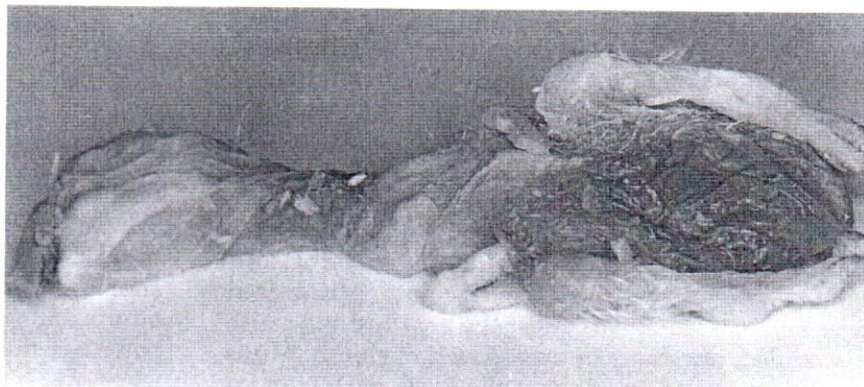Nestlings in a hot, cold or damp nest box may be stressed, fail to beg for food or be abandoned (Figure 30.2). Improper nest material may be ingested or inhaled or may support the growth of bacteria and fungi. Rats, snakes and other predators may consume nestlings or disturb the parents and prevent regular feedings. Disturbances of the nest box may cause parents to neglect or traumatize chicks.

#### Injuries

Nestlings may be injured by their parents, other nestlings or improper nest box construction (eg, exposed nails, slippery nest material). Poor nutrition can cause metabolic bone disease and make the chicks more susceptible to fractures. Many of the larger psittacines are territorial and may traumatize the nestlings when defending the nest. To prevent these injuries, the nest box can be equipped with a sliding door over the entrance hole to exclude the parents from the nest box while chicks are being examined. Chicks may also traumatize each other, most frequently injuring the beak, face and wing tips.

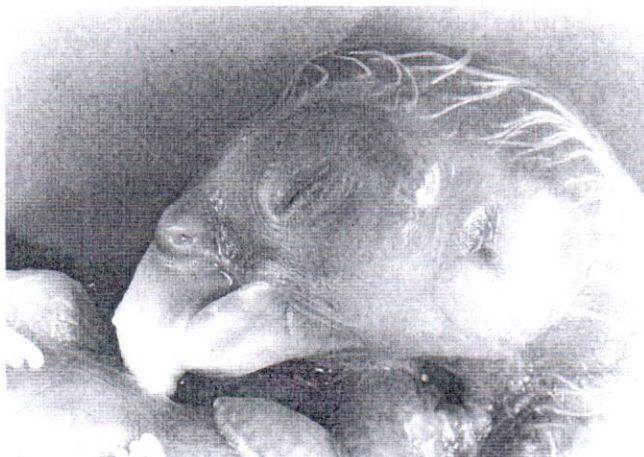#### Infectious Diseases

Microbial infections (gram-negative bacteria, chlamydia, viruses and yeast) and internal parasites (eg, giardia and trichomoniasis) are frequent causes of mortality in nestling birds (Figure 30.3). Common sources include adult birds (which may be asymp-



**FIG 30.2** Chicks may be abandoned in the nest if the parents are inexperienced, if insufficient types and quantities of food are available, if the neonate does not properly beg for food, or if the nest box is cold, hot, damp or infested with vermin. Chicks that are being raised by the parents should be observed daily, if the parents will allow it, to ensure they are receiving proper care. Neonatal mortalities may indicate disease or management-related problems within the collection that can be identified by postmortem examination.





**FIG 30.3** Any neonate or embryo that dies should be submitted for necropsy and histopathologic evaluation. This is particularly true of incubated eggs. These deaths may indicate underlying bacterial or viral infections in the flock. Note the egg tooth and membrane covering the ear in this 28-day-old Moluccan Cockatoo embryo.

matic carriers) and contaminated food, water or nest material. Ill nestlings should be pulled for hand-feeding and appropriate treatment. These birds should be raised separately from other neonates and should not be fed by the same person who cares for the other birds in the nursery. If this is not possible, some microbial infections can be treated by offering medicated food to the parents who will then feed it to the nestlings. Fortunately, adult birds are often less selective of their diet while feeding offspring and may accept foods that they would ordinarily refuse. Parents preferentially feed nestlings soft, moist food, which should be offered fresh two to three times daily. Only highly susceptible microbial infections can be treated by offering medicated food to the parents, because it is difficult to achieve adequate antibiotic concentrations in the chick by using this technique (see Chapter 17). It is also possible that a parent could feed toxic amounts of the antimicrobial agent to the chicks. Viral infections such as polyomavirus and beak and feather disease virus (PBFD) can also affect parent-raised chicks.

#### External Parasites

Red mites (*Dermanyssus gallinae*), Northern fowl mites (*Ornithonyssus sylvarium*), fire ants, Africanized bees and mosquitos can infest the nest box and cause discomfort, anemia and even death of chicks. Mites can be controlled by dusting the birds with 5% carbaryl or pyrethrin powders and spraying the cage and nest box with 5% carbaryl or 5-10% malathion. Adding a small amount of 5% carbaryl powder to the nest material will aid in control, but care should be

taken in areas where insect vectors (eg, cockroaches) might carry *Sarcocystis* sp. If cockroaches enter the nest box and die from the insecticide, they may be eaten by either the parents or nestlings and subsequently transmit *Sarcocystis* sp.<sup>9</sup> Control of other pests is described in Chapter 2. Insecticides should be used only if indicated by the infestation of a parasite. They should not be used prophylactically.

## Hand-raising Birds

### Husbandry and Preventive Medicine

Psittacine chicks are altricial, and as neonates they are unable to thermoregulate, unable to feed themselves and have a poorly developed immune system. Consequently, diet and environmental conditions have a profound impact on health. When faced with a neonatal health problem, it is essential for the clinician to carefully evaluate the environmental conditions, hygiene practices and feeding methods in the nursery. Books are available on hand-feeding practices and it is beyond the scope of this chapter to completely discuss all aspects of hand-raising. The purpose of this section is to introduce the avian veterinarian to the most important factors to consider when investigating neonatal health problems (Table 30.1). Possibly one of the most overlooked factors in raising healthy psittacine chicks is providing them with ample rest periods in which they are not disturbed between feedings.

#### Nursery Design

Careful design can increase the function of the nursery and aid in disease prevention. The nursery should be separated from any contact with adult birds, and the aviculturist should take steps to prevent disease transmission from the adult flock. It is best to have separate caretakers for the adults and the babies. If this is impossible, the aviculturist should shower and change clothes between caring for adults and young. It is advantageous to have several potential nursery rooms in case there is a disease outbreak. If possible, valuable or endangered species should be raised in a room separate from common species that have a high incidence of infectious diseases (eg, budgerigars, cockatiels, lovebirds and conures). The nursery room(s) should have adequate



**TABLE 30.1 Guidelines for Nursery Management**

1. Every nursery should have a separate room where sick birds can be isolated. This room should not share air flow with the primary nursery. Nestlings showing signs of disease should be immediately moved from the primary nursery and isolated.
2. If a baby leaves the nursery for any reason and is exposed to other birds, it should not be returned to the primary nursery.
3. A nestling should never be added from another facility.
4. The same people should not care for both the adults and the neonates, unless special precautions are taken to avoid disease transmission.
5. Visitors, especially people who own birds, should be restricted from entering the nursery. People can act as mechanical vectors of infectious agents.
6. Ideally, every bird that is sold should be tested for microbial diseases, PBFD virus and polyomavirus before shipment.
7. Thorough cleaning of nursery facilities and equipment is better than partial cleaning followed by the use of disinfectants. Disinfectants are toxic, and exposure to the nestlings should be minimized (both direct contact and fumes).
8. Proper feeding practices can minimize problems.
  - a. Use a proven diet and constantly evaluate growth by assessing development and comparing weight gains with a growth chart.
  - b. Store dry nestling diet in a cool, dry, rodent-free area. Opened food containers should be stored in the freezer.
  - c. Feeding formula should be carefully measured and mixed, and the temperature checked before feeding.
  - d. Mix food fresh for each feeding. Do not store mixed food in the refrigerator and feed it at a later time.
  - e. Use an individual syringe for each nestling.
  - f. Never feed a bird and place the syringe back in the feeding formula.

temperature control and be self-contained with a large sink for washing hands and feeding utensils, a scale for weighing birds, a coffee-maker or hot plate for heating water or food and simple shelves for holding the brooders and enclosures. The room should be kept uncluttered to allow easy and complete cleaning, and the walls should be covered or painted with a durable, non-porous surface that can be easily disinfected. In areas where power outages are common, an alarm or back-up electrical system should be considered. An evacuation and emergency plan is best designed prior to a disaster.

### Age at Time of Removal from the Nest

For most species, nestlings less than two to three weeks of age are easiest to adapt to the hand-feeding process. Older birds may be fearful of people and more difficult to feed, while younger chicks more readily accept hand-feeding but must be fed more frequently. Chicks hatched from artificially incu-

bated eggs must be hand-raised or fostered from the first day. To help control some diseases, many aviculturists feed only babies hatched from artificially incubated eggs and are careful to exclude parent-hatched nestlings. Several viral infections (eg, PBFD and polyomavirus) that can be egg-transmitted may not be prevented by incubating eggs.<sup>27,28</sup>

### Housing


Chicks should be housed in brooders in order to provide the precise temperature and humidity control required for optimal development of young neonates. Older chicks can tolerate wider temperature fluctuations. Commercially available brooders vary widely in quality and design. Solid state thermostats are more reliable than wafer types, and a back up thermostat should turn the unit off if the temperature becomes too high. Air should be circulated with a gentle fan. Commercial models with powerful fans should be avoided because they can dehydrate the chicks. Inside the brooder the chick should be kept in a small plastic container lined on the bottom with soft, absorbable paper toweling to aid in support and provide security. Slick surfaces can cause leg deformities. Chicks can also be housed in containers with a raised floor made of plastic-coated wire. These units keep the neonates clean and dry by allowing excrement to fall through the wire mesh; however, the mesh must be small enough to prevent the leg (especially the tibiotarsal joint) from extending through the wire. The container should have smooth walls to prevent the chick from entrapping its wings or beak (Figure 30.4).

Partially feathered chicks can be housed in open plastic pans or aquariums if the nursery is properly heated. Fully feathered chicks are capable of flight and should be kept in secure enclosures. Their wing feathers should be clipped after they are fully developed.

### Temperature and Humidity

The nestling's age and amount of feathering determine the optimal environmental conditions. The relative humidity for tropical species should be above 50 percent. Temperature should be adjusted for the behavior of the particular bird. Birds that are too hot will pant and hold their wings away from their bodies; those that are too cold will huddle, shiver and may have slow crop-emptying times. Chicks housed at temperatures outside the optimal range will grow more slowly. Some suggested temperatures for psittacine chicks are provided in Table 30.2.





**FIG 30.4** Plastic-coated wire baskets with raised floors are excellent for housing psittacine neonates greater than ten days of age. The size of the floor mesh can be varied to accommodate different sized chicks. This enclosure design keeps the neonates clean and dry, and can be placed inside most commercially available brooders (courtesy of Apalachee River Aviary).

**TABLE 30.2** Suggested Ambient Temperature Ranges for Psittacine Chicks

Recent hatchlings	92-94°F
Unfeathered chicks	90-92°F
Chicks with some pin feathers	85-90°F
Fully feathered chicks	75-80°F
Weaned chicks	68-75°F

The actual temperature should be adjusted according to the needs of the individual chick.

### Substrate

The substrate on the floor of the "nest" should absorb moisture from the droppings, provide firm footing and not cause major digestive problems if ingested. Cloth diapers or unfrayed cotton woven towels and coated wire screens can be used with few problems. Problem substrates include tissue paper (provides



**FIG 30.5** Drop-through, raised floor units are preferable for housing growing chicks in the nursery. If other types of containers are used, the bottom should be covered with cloth diapers or woven cotton towels. Wood shavings, wood chips, cat litter and pelleted bedding can cause respiratory, gastrointestinal or dermatologic problems.

poor traction), soft, crumpled or shredded paper, wood shavings or chips (cause impactions if ingested), sawdust (causes respiratory problems if inhaled), and coarse pelleted bedding (causes GI irritation or blockage if ingested) (Figure 30.5). Substrate consumption may even result in malnutrition.

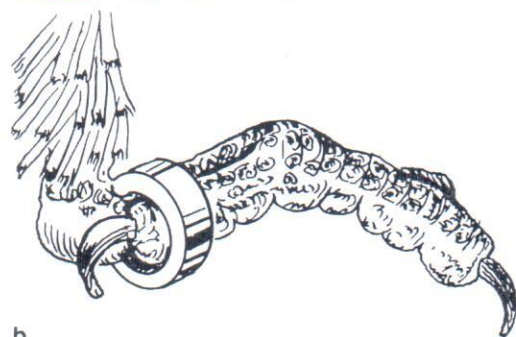

### Housing Multiple Chicks

Nestlings seem to grow best if they are housed with their clutch mates; however, chicks should be separated if there are substantial differences in body size, or if a bird becomes ill. Housing birds from different clutches together is discouraged because of the threat of disease transmission. Chicks should be housed individually if there is a disease outbreak in the nursery. Neonates or visitors from another collection should be discouraged from entering the nursery.

### Chick Identification

Chicks should be assigned individual identification numbers upon entering the nursery and identified by closed banding or transponder implants when they are large enough. Closed bands are rings that are slipped over the foot at the mid-pin feather stage and become fixed in place over the metatarsus as the foot grows too large for the band to be removed (Figure 30.6).<sup>10,21</sup> Electronic microchip transponders can be intramuscularly or subcutaneously implanted and provide permanent identification.<sup>10</sup> At a minimum, the aviculturist should record the following information in a log book: egg number if artificially hatched, identification of siblings and parents and location of





b

.6 Many states require that domestically raised neonates be banded. The band is applied by **a)** placing digits 2 and 3 facing forward and **b)** slipping the band over the metatarsal. The size recommendations of the manufacturer of various bands should be carefully followed.

parents' enclosure. Recording the health history of the parents and siblings is also helpful if epidemiologic information is required for disease investigation. Permanent identification is required for international sale of CITES-listed species and shipment to some states.

### Diets

Numerous hand-feeding diets are available, and a diet that works for one facility may not work well in another. Apparently, the idiosyncracies of the feeder's techniques and the amount and frequency of feeding influence growth as much as the composition of the diet. Therefore, a *carte blanche* recommendation for a particular diet cannot be made. Manufacturers of commercial diets are listed in Table 30.3 and examples of homemade diets are given in Table 30.4. The advantages of commercial diets are that they are easier to prepare and have more consistent nutritional content.

Most of the nutritional requirements of psittacine chicks are not known, and the development of successful hand-feeding diets has been based largely on

**TABLE 30.3** Manufacturers\* of Hand-feeding Diets for Psittacine Chicks

1. AviSci Inc., P.O. Box 598, Okemos, MI 48805
2. Harrison's Bird Diets, Omaha, NE, (800) 346-0269
3. John Vanderhoof, P.O. Box 575, Woodlake, CA 93286
4. Kaytee Products, 292 Grand, P.O. Box 230, Chilton, WI 53014
5. Kellogg's Inc., P.O. Box 684, Milwaukee, WI 53020
6. Lafeber Co., RR #2, Odell, IL 60460
7. Lake's Minnesota Macaws, Inc., 639 Stryker Ave., St. Paul, MN 55107
8. Marion Zoological Inc., 113 N. First, P.O. Box 212, Marion, KS 66861
9. Pretty Bird International, 1170 Eagan Industrial Rd., Eagan, MN 55121
10. Rolf C. Hagen Inc., 3225 Sartelon St., Montreal, Quebec, Canada H4R1E8
11. Roudybush Inc., P.O. Box 908, Templeton, CA 93465-0908
12. Topper Bird Ranch Diets, 1466 N. Carpenter Rd., Modesto, CA 95351
13. Zeigler Brothers, P.O. Box 95, Gardners, PA 17324

Listed in alphabetical order.

\* Listing or absence of listing in this table does not imply endorsement or non-endorsement by the authors or editors.

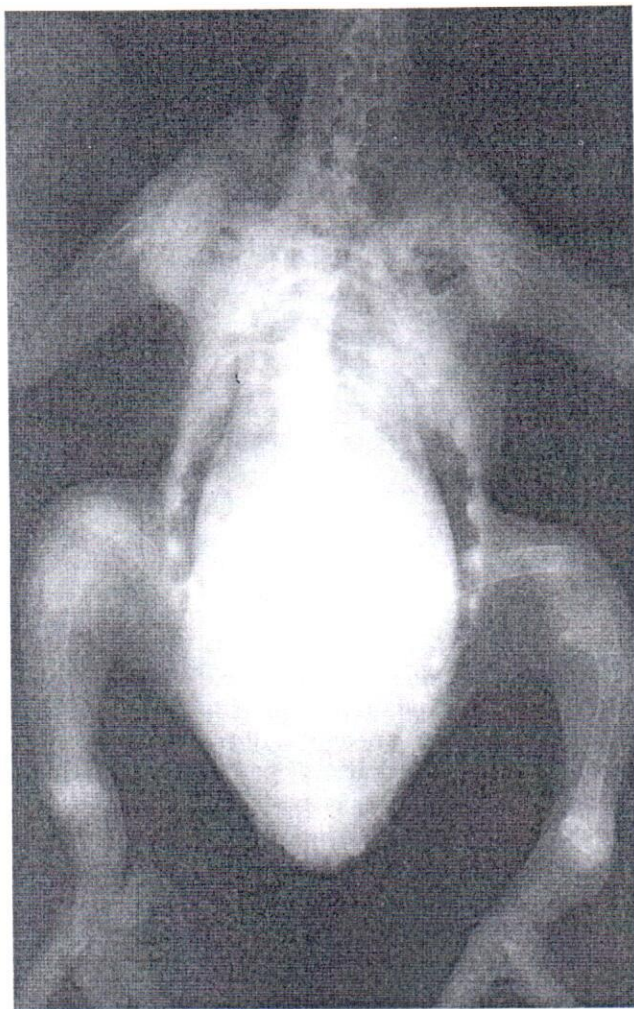trial and error and extrapolation from the dietary requirements of poultry (Figure 30.7). Some generalizations regarding neonatal nutrition can be made. Investigations in cockatiels<sup>30</sup> and the observations of numerous aviculturists indicate that the protein content should be approximately 18 to 22%, calcium 1%, and calcium and phosphorus should be balanced in approximately a 2:1 ratio. Lists of specific nutrient deficiencies and associated clinical signs are often published for poultry but may not be applicable to psittacine birds. For example, lysine deficiency causes depigmented feathers in poultry but not in cockatiels. Choline deficiency has been shown to be associated with feather depigmentation in cockatiels.<sup>30</sup>

The water content, consistency and temperature of the feeding formula are also important. A diet containing approximately 25 to 30% solids (70-75% water) should be fed to nestlings older than one or

**TABLE 30.4** Primate Diet Hand-feeding Formula Used With Success in Some Nurseries


1. Grind primate diet.
2. Mix (by weight)
  - Ground primate diet 50%
  - Commercial hand-feeding formula 25%
  - Dry oatmeal baby cereal 25%
3. Store mixed dry diet in a sealed bag in the freezer.
4. Heat water to approximately 120°F. Add 20 to 25 mls of the heated water to 25-30 gms of the dry mixture. Stir in 1 teaspoon of creamed carrots and 1 teaspoon of mixed baby cereal (from a jar).
5. Mix thoroughly and feed at a temperature of 102 to 105°F.





**FIG 30.7** A three-week-old Blue and Gold Macaw chick was presented with a three-day history of inability to ambulate and the appearance of ulcerations on the abdominal body wall. The bird was being fed a homemade diet. The limbs were soft and pliable. Radiographs indicated osteopenia and pathologic fractures in the humerus and tibiotarsus suggestive of metabolic bone disease (rickets). Note the soft tissue opacity of the abdomen, a relatively normal finding in young chicks. The liver, proventriculus, ventriculus and intestines (the last three of which stay filled with food) generally fill the entire abdominal cavity (courtesy of Marjorie McMillan).

two days.<sup>30</sup> It may be beneficial to feed a more dilute diet for the first day after hatching because the chick will be using the contents of its yolk sac for nutrition. Inexperienced hand-feeders should actually weigh the solid and liquid portions of the diet to ensure a proper dilution is fed. Evaluating a cooked diet according to visual consistency is inaccurate. Cooked starches may cause the formula to appear thick even though the percentage of solids is very low. The food should be warmed to 101°-104°F and the temperature measured with an accurate thermometer. The instructions provided with commercial diets should



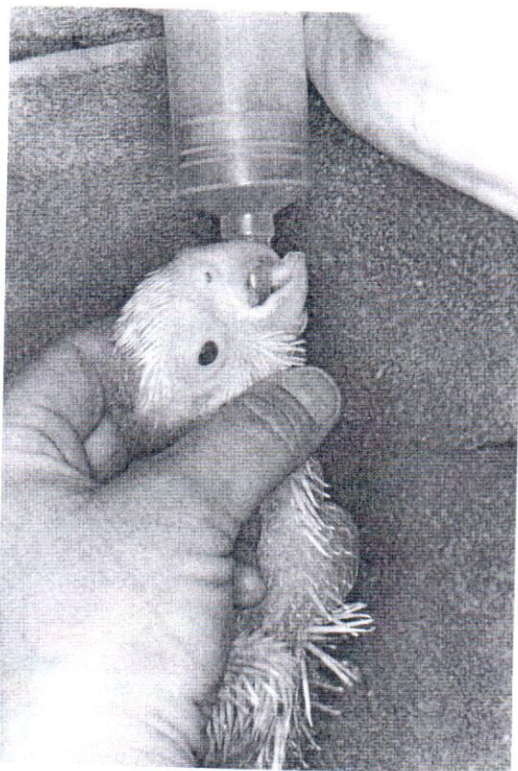**FIG 30.8** Coffee makers and hot plates are better for heating for formula for neonates than microwave ovens. Microwave ovens tend to create super hot spots in the formula that can full-thickness burns in the crop (see Color 13).

be carefully followed. Cooler food may be refused; food may scald the crop. A hot plate or coffee maker should be used for heating formula. The use of a microwave oven for heating food frequently results in severe crop burns (Figure 30.8).

### Feeding Methods

Most aviculturists now use syringes for feeding, though bent spoons or crop tubes are occasionally used. Catheter-tipped syringes are especially popular. Hungry nestling birds display a feeding response that consists of rapid, thrusting head movements bobbing up and down. These movements can be stimulated by touching the commissures of the mandible or pressing lightly under the mandible (Figure 30.9). While the bird is displaying this behavior, the gape is closed and large amounts of food can be delivered quickly with less fear of passing food into the trachea. If a neonate resists feeding or a feeding response is not displayed, the chance of tracheal aspiration is greater. If a young bird that is not eating on its own refuses to eat for two to three feedings in a row, it may be having a medical problem that should be evaluated. As some birds get older, they display less of a feeding response and are more difficult to feed. This may be an indication that weaning is beginning to occur. If an older bird resists feeding, that feeding should be skipped. The chick may be hungrier and more willing to eat at the next scheduled feeding. A long, soft tube can be used to feed recalcitrant birds. Short tubes should not be used, as they may be detached from the syringe and swallowed.





**FIG 30.9** A neonate with an active feeding response will rapidly thrust the head up and down on a syringe. The head should be gently supported to prevent injuries during the feeding process (courtesy of Apalachee River Aviary).

### Feeding Amounts and Frequency

Younger birds should be fed more often than older, larger birds. Adequate weight gain and good morphologic development are more important indicators of adequate nutrition than the amount or number of feedings. The amount of food and frequency of feeding depends on the age and development of the chick and the particular diet fed. Birds one to five days old should be fed six to ten times daily; chicks with eyes closed, four to six times daily; chicks with eyes opened, three to four times daily; and birds with feathers emerging, two to three times daily. Chicks less than one week old may benefit from around-the-clock feeding, but it is not necessary to feed older chicks through the night. The last feeding can be given between 10:00 p.m. and 12:00 a.m. and the first between 6:00 and 7:00 a.m. The crop should be filled to capacity and allowed to nearly empty before the next meal. The crop should be allowed to completely empty at least once each day (usually in the morning following the final night feeding). It is important to feed young birds the maximum amounts of food early to stimulate good growth and increase crop capacity. However, excessively large meals in very small birds

can predispose them to regurgitation and subsequent aspiration. In these birds, it is best to feed smaller quantities of food on a more frequent basis. Some formulas have higher fiber content that allows for longer periods between feedings and less total food volume per day due to improved feed efficiency.

### Weaning

Weaning is a stressful time for both the bird and the hand-feeder. Some birds wean themselves at the appropriate body weight by refusing to be hand-fed, but many others must be encouraged to wean (particularly cockatoos and large macaws).<sup>30</sup> Several weeks prior to the expected age of weaning, the bird should be offered a variety of foods such as corn, cooked vegetables, various fruits, soaked monkey chow, formulated diet, spray millet, hulled seeds and peanut butter and jelly sandwiches. Seeds with hulls and large chunks of food should be avoided because at this stage the bird may consume them whole. Most birds will pick up and play with food long before they actually consume the material. To encourage experimentation, food bowls should be easily accessible and placed at perch height. The presence of an older, self-feeding bird may encourage younger birds to wean more quickly. It is best to accustom a weaning baby to a wide variety of formulated diets and fresh fruits and vegetables. This will make them more likely to accept the varied diets that they may be offered when they leave the nursery. If birds are weaned onto a specific diet, it is important that a new owner continue feeding the same diet until the bird is accustomed to its new surroundings and the diet can be safely changed.

When the bird is at the right weight and development or consuming some solid food, the midday feeding should be gradually eliminated, followed by the morning and then the evening meals. If the bird was fed properly to begin with, weight loss in the range of 10 to 15% of the peak body weight may be expected during the weaning process. If the bird was underweight to begin with, any weight loss may be abnormal. Subclinical illness (especially gram-negative bacterial infections of the alimentary tract) may become apparent during weaning. Clinical signs could include excessive weight loss, slowed crop-emptying times, depression, diarrhea, regurgitation or simply a failure to wean. If problems are noted, weaning should be postponed and the underlying problem diagnosed and treated. If the weight loss is severe, it may be necessary to resume hand-feeding two to three times daily, and weaning should not be re-attempted until the bird has gained adequate weight.



Some birds will resist hand-feeding before they are capable of maintaining adequate body weight on their own. This is especially common in malnourished birds that are stunted in growth but of weaning age. It may be necessary to tube-feed these birds, because forcing them to hand-feed increases the risk of aspiration and causes severe stress.

### Hygiene

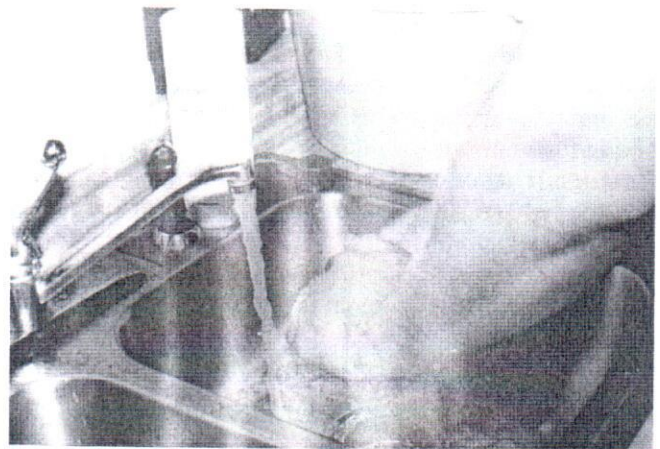
Careful control of environmental sources of pathogenic bacteria and yeast are essential for maintaining healthy chicks. A diligent, thorough, common-sense approach that includes minimum exposure to harmful chemicals works best. The most important sources of microbial contamination include the food, water supply, feeding and food preparation utensils, other birds in the nursery and the hand-feeder. If microbial infections are repeatedly encountered in a nursery, these areas should be cultured in order to identify and eliminate the source of contamination.

Microbes in the food and water that would have little effect on adult birds can cause life-threatening infections in neonates. Yeast, *Escherichia coli*, *Klebsiella*, *Enterobacter* and *Pseudomonas* spp. are common contaminants. To avoid these microbes, the components of the diet should be carefully selected. Most commercial diets are relatively clean. Products intended for poultry, however, may contain high levels of bacterial contamination and should be excluded from the diet.<sup>17</sup> Monkey chow is a common ingredient in homemade diets and can be used successfully if properly stored (Figure 30.10). Yeast and bacterial contamination of any formulated diet can occur if it is improperly stored. *Pseudomonas* is a frequent contaminant of water taps and bottled water dispensers.

The diet should be mixed fresh before each feeding. As a guide, the standards for cleanliness in a nursery should be higher than the feeders would maintain for themselves. Opened containers of dry baby formula should be stored in sealed containers in the freezer. Powdered baby formula that has been mixed with water should never be stored and fed to babies in subsequent feedings. Hands should be washed between birds or groups of birds to avoid transmitting diseases (Figure 30.11). A separate syringe should be used for each bird and the syringes should be filled in advance. Under no circumstances should a syringe used to feed a bird be dipped back into the food for a refill; this will result in the spread of infectious agents throughout the nursery. The syringes and all implements used for preparing food should be kept clean by disassembling, scrubbing and disinfecting



**FIG 30.10** All avian food stuffs should be maintained in sealed containers in cool, moisture-free areas. All rodent, insect or feral bird exposure to the food must be prevented. Several bacteria disease outbreaks in nurseries have been blamed on specific types of manufactured food when, in fact, the outbreaks were the result of careless food handling (eg, wet food or food contaminated by rodent droppings) on the part of the aviculturist (courtesy of: Apalachee River Aviary).



**FIG 30.11** Nursery hygiene is critical in preventing infectious disease outbreaks. In addition to maintaining the neonates in a clean, dry environment, aviculturists must also make certain they do not serve as sources of infection for their neonates. Part of personnel hygiene involves thoroughly washing the hands before handling any neonate. Hands should also be washed when moving from one group of neonates to the next.

after each use. Quaternary ammonium products containing a detergent are recommended for disinfection since they will cause less drying of the syringe



plunger than Clorox.<sup>10</sup> The syringe plunger should be periodically removed and scrubbed to avoid a build-up of food and pathogens. Feeding implements must be thoroughly rinsed to reduce exposure of chicks to residual disinfectants.

### New Additions

New additions to the nursery should be placed in separate brooders, fed last and monitored carefully until it is apparent that they are healthy. It is prudent to culture the cloaca of new birds at the time they enter the nursery to diagnose and eliminate potential microbial infections that might spread to other chicks. A cloacal swab can also be submitted to make certain that the neonates are not shedding polyomavirus. Detecting an infectious agent in a newly introduced chick also indicates that the parents and egg incubator should be evaluated. In this manner, chicks can be used to monitor the health of the adult collection. A clinical workup and brief isolation period of all new arrivals to the nursery will help prevent some diseases but will not eliminate all risks. For example, chicks infected with PBFD virus or polyomavirus may not show clinical signs of disease for weeks to months after exposure. Antigen detection tests may be used to identify potential carriers of these diseases<sup>28</sup> (see Chapter 6). Birds from other collections should *never* be brought into a nursery.

### Evaluating Nestling Birds

Nestling psittacine birds can be evaluated in the same way as adult birds. A complete history, thorough physical examination and appropriate laboratory tests should be completed. The unique features of neonatal psittacine birds are emphasized in the sections below.

#### History

Avicultural clients should be asked to prepare a written summary prior to taking a nestling psittacine chick to the veterinarian. The history should include the following:

1. The past breeding and health history of the parents and condition of the chick's siblings.
2. Problems during incubation or hatching if the chick was artificially incubated. (Chicks that have problems hatching frequently grow poorly during the first few weeks of life and may be stunted).
3. Brooder temperature, substrate, hygiene practices (including exposure to any disinfectants) and condition of other birds in the nursery.

4. The type of diet, percent solids content, how the diet is prepared, amount and frequency of feedings and implement used to feed the chick.
5. The identification number and method used to identify the chick.

### Body Weight Charts

One of the most valuable tools for evaluating nestling birds is a chart recording daily body weight. Birds should be weighed prior to the morning feeding when the crop and GI tract should be relatively empty (Figure 30.12). At most stages of development, juvenile birds should gain a certain amount of weight daily. Failure to gain this amount of weight is cause for concern. Almost any disorder will affect the weight gain, and lack of a normal weight gain is often one of the earliest signs of problems. Body weight can be compared to weight charts developed from records of morphologically normal birds to assess normal development; however, it must be stressed that there is wide natural variation in the normal growth rates of chicks depending on individual body conformation, gender and feeding practices. See Table 30.5 for suggested normal growth rates for selected psittacine species.



FIG 30.12 Chicks should be weighed each day before the morning feeding to monitor growth and to detect problems in an early stage.



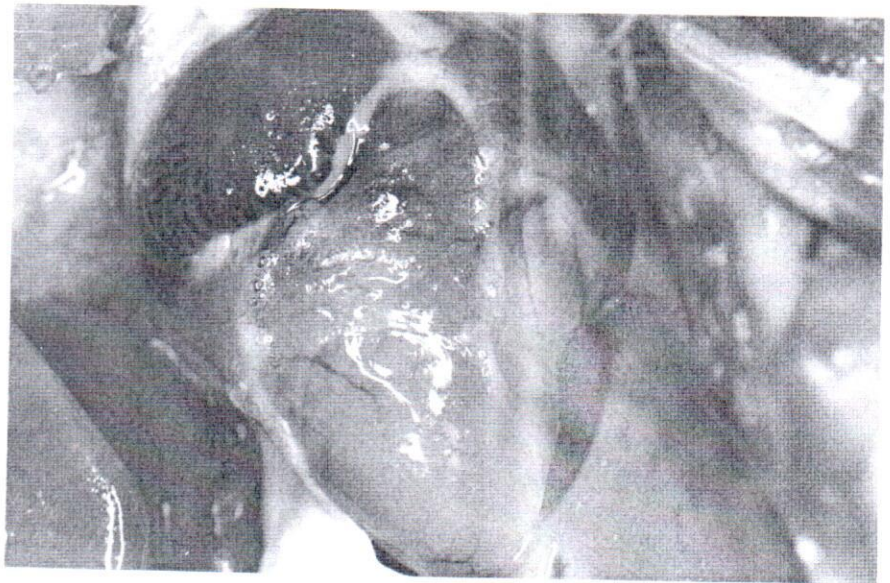Extensive discussion of the normal growth of psittacines has been published.<sup>11,21</sup> Growth is slow for approximately one to four days following hatching and then accelerates logarithmically until a second plateau stage just prior to weaning, when many birds will achieve body weights that exceed their adult weight. During weaning, this extra weight is lost as the bird exercises more and assumes more adult proportions.

### Developmental Characteristics

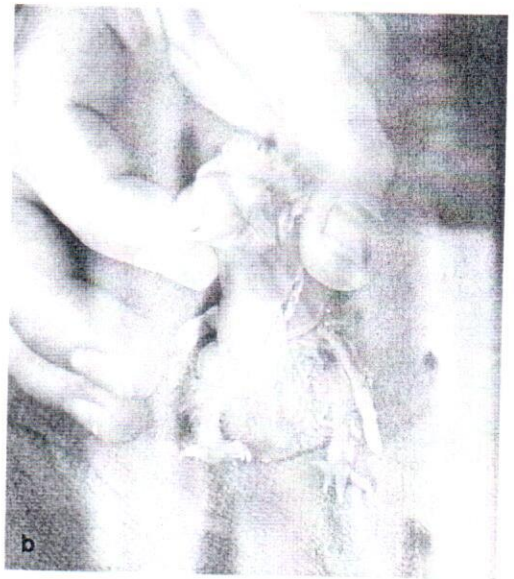Recording developmental characteristics, such as the date the eyes open, the first appearance of head, wing and tail feathers and any other physical changes will help in assessing the growth of a chick. As a generalization, growth characteristics vary with body size, and larger species develop more slowly. The growth rate may be as high as 17% a day during the first week. Growth characteristics for a number of psittacine species have been reported.<sup>11</sup> Delayed developmental characteristics usually indicate delayed overall growth and stunting.

### Physical Examination

A thorough physical examination is as important in nestlings as it is in adults. During the examination, chilling and stress should be avoided by warming hands, warming the room and keeping handling times to a minimum. Birds with food in the crop should be handled carefully to avoid regurgitation and aspiration. The heart and lungs should be auscultated to detect cardiac murmurs and moist respiratory sounds (Figure 30.13). The eyes and ears should be carefully examined to evaluate normal development and opening. It is normal to have a clear discharge from the eyes when they open. In macaws, the eyes usually open between 14 and 28 days following hatching; in cockatoos, between ten and 21 days;

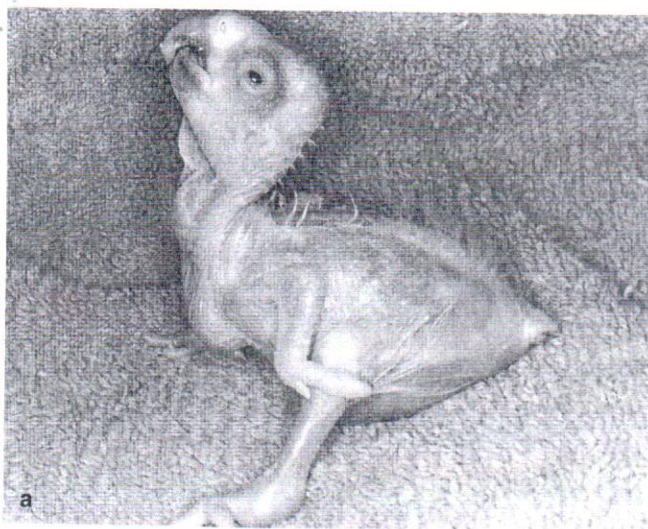

**FIG 30.13** A five-week-old Blue and Gold Macaw chick was presented for regurgitation and retarded growth (the younger sibling weighed 120 g more than the patient). The bird was severely dyspneic and depressed. The crop was partially filled with food but peristaltic activity appeared to be normal. Auscultation of the heart revealed a severe murmur. The bird did not respond to supportive therapy. At necropsy, the heart was enlarged and a ventricular septal defect was identified.



**FIG 30.14** a) An eight-week-old African Grey parrot was presented with severe torticollis (the head rested on the ground when the bird was upright). The bird's head had been turned at an angle since hatching. Radiographs indicated a positional deformity in the cervical vertebrae. A mate was purchased. Improper incubation parameters, nutritional deficiencies in the hen, infectious diseases, improper chick position in the egg, and genetic flaws have all been proposed as etiologies of spinal deformities. b) A three-day-old Blue and Gold Macaw chick was presented for severe torticollis. The abnormality was corrected within two weeks of hatching a neck brace courtesy of Martin Ortlieb.





**FIG 30.15** Until weaning, neonates like these **a)** two-week-old and **b)** four-week-old Moluccan Cockatoo chicks will stand on their hocks with their abdomen on the ground for support. A normal chick will be bright and alert, with the head raised in response to any activity that may suggest that it is feeding time.

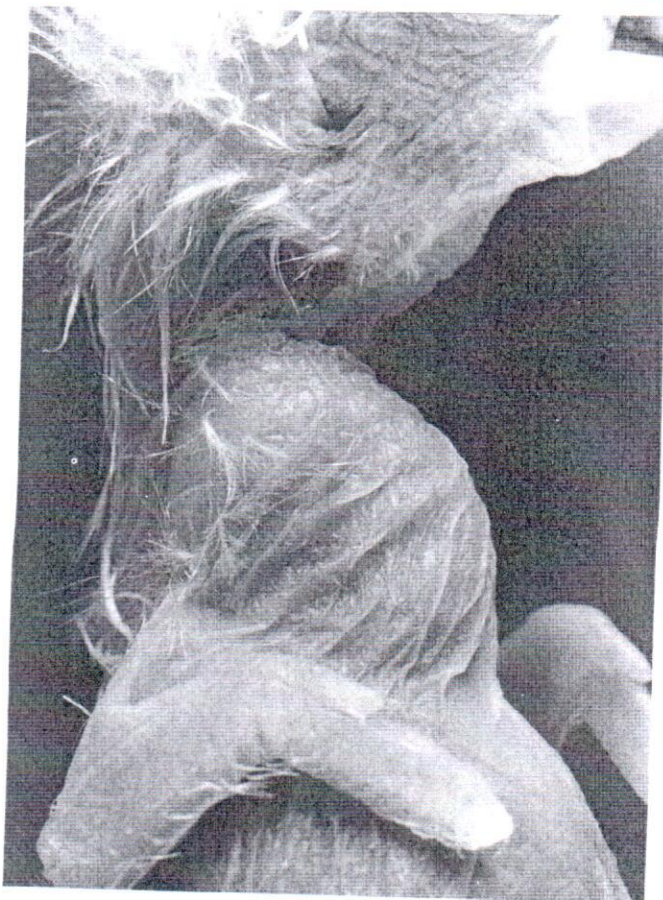and in Amazon parrots, from 14 to 21 days. The ears are open at hatching in Old World Psittaciformes, and open from ten to 35 days of age in neotropical species. Nestlings can be examined in the same manner as adults but have physical characteristics that differ from adult birds. Particular attention should be paid to body conformation, spine and neck curvature and beak alignment and curvature (Figure 30.14).

#### Posture

Nestling birds sleep much of the time and are most active when hungry. They may sleep in almost any position, including sprawled with their legs in the air. Until weaning, they sit on their hock joints, rather than up on their feet, using their protuberant abdomen to create a tripod stance (Figure 30.15). Young birds may be uncoordinated and splay their legs when trying to walk. This should be considered normal unless a limb is held consistently in an abnormal position.

#### Body Conformation

Nestlings have relatively little muscle mass and a large, protuberant abdomen. The pectoral muscles are almost nonexistent. As the bird ages, the muscle mass will increase, but even at weaning they will be thinner than in an adult. Body mass in young nestlings is best assessed by noting the thickness of the muscle and subcutaneous fat covering the elbows, oes and hips. In contrast to adults, nestlings have a very full abdomen because the ventriculus and proventriculus are greatly enlarged at this age.



**FIG 30.16** The normal skin of a nestling should be yellowish-pink, supple and warm. A neonate that is being properly cared for by the parents will always have a full crop, as seen in this neonatal Umbrella Cockatoo.



TABLE 30.5 Sample Weight Gains (in grams) of Selected Hand-raised Psittacine Birds and Normal Adults

Age (in days)	0	3	7	14	21	28	35	42	49	Adult
Cockatiel	4-6	5-6	12-14	45-65	72-108	80-120	80-90	80-95	90-110	90-110
Golden Conure	7-11	10-12	12-23	20-25	30-100	45-150	90-240	125-270	180-310	262
Green-cheeked Amazon Parrot	10-14	15-22	30-50	90-135	200-250	225-310	280-350	290-350	***	360
Lilac-crowned Amazon Parrot	11-13	15-20	25-35	75-140	160-240	250-300	300-350	310-350	***	360
Blue-fronted Amazon Parrot	14-17	20-25	35-60	100-170	240-280	280-370	350-420	380-440	380-430	432
Yellow-headed Amazon Parrot	12-21	16-30	25-50	75-200	140-300	230-450	270-580	310-560	380-565	568
Yellow-crowned Amazon Parrot	12-15	15-33	25-55	70-170	175-260	250-360	350-440	400-480	***	500
Yellow-naped Amazon Parrot	11-18	16-35	28-75	60-200	170-360	275-500	420-600	500-650	500-650	596
Eclectus Parrot	12-20	16-35	23-60	60-150	110-240	190-350	260-440	300-450	320-480	432
African Grey Parrot	11-17	15-211	25-40	70-120	135-250	240-335	300-440	380-470	435-500	554
Red-vented Cockatoo	11	16-20	25-30	70-100	145-200	230-280	250-300	275-350	230-350	298
Citron-crested Cockatoo	12-15	15-23	26-84	78-144	148-265	208-366	292-430	319-445	320-464	357
Bare-eyed Cockatoo	8-14	11-35	18-70	48-170	99-308	167-363	238-415	283-410	289-415	375
Goffin's Cockatoo	8-11	10-15	20-45	70-100	125-240	175-275	220-325	250-350	250-350	255
Lesser Sulphur-crested Cockatoo	8-15	12-22	25-60	65-120	140-250	225-320	280-340	315-380	320-410	450
Rose-breasted Cockatoo	7-12	10-17	15-40	35-100	70-200	115-300	175-370	220-400	240-423	403
Medium Sulphur-crested Cockatoo	12-15	18-25	35-70	65-140	160-250	240-350	340-450	400-525	450-550	465
Major Mitchell's Cockatoo	9-13	13-22	25-55	55-130	140-220	210-300	270-375	290-450	340-500	423
Umbrella Cockatoo	12-20	15-20	25-55	75-150	170-300	280-400	350-530	450-600	500-725	577
Triton Cockatoo	11-19	15-30	30-70	90-170	200-325	290-475	400-650	450-750	490-800	643
Moluccan Cockatoo	16-22	21-30	35-55	90-170	190-300	330-450	470-650	600-750	680-825	853
Greater Sulphur-crested Cockatoo	16-20	18-35	35-80	100-200	220-330	370-525	450-625	500-725	550-880	843
Yellow-collared Macaw	9-15	12-20	25-35	60-90	110-160	190-240	230-280	250-290	270-300	250
Red-fronted Macaw	12-16	18-25	25-45	70-130	140-250	230-360	330-470	405-530	465-580	490
Caninde Macaw	14-22	19-25	30-45	70-120	165-250	275-420	420-600	520-725	600-800	752
Military Macaw	17-26	24-45	35-170	85-300	220-425	360-650	500-800	600-950	680-1050	925
Scarlet Macaw	17-26	25-45	40-65	90-175	200-400	380-625	540-800	720-1050	830-1150	1001
Blue and Gold Macaw	16-27	25-40	40-100	90-250	200-450	350-650	525-900	670-1100	800-1200	1039
Green-winged Macaw	17-28	30-55	45-80	100-250	225-450	400-650	610-900	830-1030	990-1190	1194
Buffon's Macaw	20-26	25-35	40-70	100-170	250-500	450-750	650-900	850-1100	1050-1350	1290
Hyacinth Macaw	20-27	25-35	45-75	110-180	250-400	450-600	600-750	800-1000	900-1200	1355

Weight ranges were derived from the weight gain records of birds hand-raised from hatching to weaning. They are provided as suggested range only, as growth of an individual chick is dependent on hatch weight, body structure, sex, diet and feeding and husbandry practices. Comparison data from two successful nurseries has indicated that birds with widely divergent body weights can successfully wean.<sup>10,20</sup> Birds in the lower end of the weight range are more prone to stunting and should be carefully observed. Birds in the upper end of the weight range may shed excess weight at weaning. Data from this table should be combined with observation of the conformation and physical condition of the chick before deciding if an individual is stunted in growth. All weights are given in grams.



### Skin

It is important to evaluate both texture and color of the skin. Normal nestlings have yellowish-pink skin with a supple, warm feel (Figure 30.16). Dehydrated nestlings will have dry, hyperemic skin that feels sticky to the touch (Color 30.4). Nestlings with white, cool skin are either hypothermic or moribund and need immediate attention. Some flaking of the skin is normal; excessive amounts of flaking indicate dehydration or exposure to high temperature, low humidity or malnutrition.

### Feather Growth

Most psittacine chicks are naked at hatch except for a sparse coating of down (Color 30.1). The first feathers appear on the head, wings, and tail, followed by feather emergence on the rest of the body (Figure 30.17). Gross discrepancies in the pattern of feather development may indicate stunted growth. Feather dysplasia (eg, pinched off feathers, constrictive bands, blood in the rachis) or epilation may indicate polyomavirus, PBFD virus, adenovirus or bacterial folliculitis. Neonates being treated with antibiotics may also have abnormally developed feathers.<sup>28</sup>

### Crop

Nestling birds have a greater crop capacity per body weight than adults, sometimes as much as two to three times the adult volume (Figure 30.18). The crop should empty at least once daily; overstretched, damaged and atonic crops will not empty properly. The



**FIG 30.18** The crop capacity of neonatal birds is larger than in an adult when compared on a per weight basis. Neonates should be fed the maximum volume of food that does not over-stretch the crop (courtesy of Apalachee River Aviary).

crop should be palpated for foreign objects and trapped, doughy food, and examined externally for redness or scabs that might indicate a burn or puncture (Color 30.12).

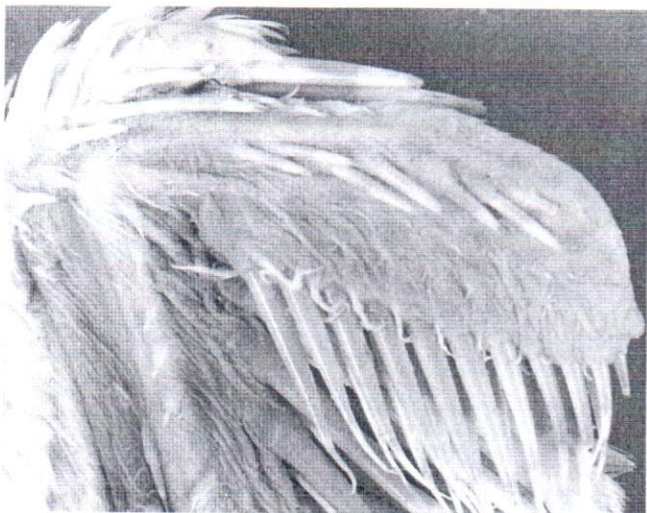### Droppings

Nestlings often have polyuric droppings. This usually results from the liquid diet they are fed. The fiber content of some formulated diets is higher than homemade formulas, and the droppings from birds fed those diets are less watery and more formed.

## Diagnostic Procedures

### Clinical Pathology

The clinical pathology of nestling psittacine birds is poorly documented; however, recent publications have established reference intervals for some species.<sup>12-14</sup> In general, nestling birds normally have lower packed cell volumes (20's-30's), lower total protein (1-3 g/dl), and higher white blood cell counts (20,000-40,000) when compared to adults of the same species (see Appendix). Young chicks also have lower plasma concentrations of albumin and uric acid and higher concentrations of alkaline phosphatase and creatine phosphokinase. It is very important to note these age-related differences in hematology so that



**FIG 30.17** Feather growth occurs rapidly in neonatal birds and follows a set pattern that varies among species. In general, feather growth starts with the head, wings and tail, followed by feather emergence on the rest of the body. This figure shows normal pin feather development in the carpus and distal portion of the radius and ulna of a five-week-old Umbrella Cockatoo.



misinterpretation of laboratory values does not result in the unnecessary treatment of a normal chick.

### Microbiology

Young birds are highly prone to microbial infections and cloacal cultures, and fecal Gram's stains should be routinely evaluated during development. Normal aerobic cloacal flora is gram-positive and consists of *Lactobacillus*, *Corynebacteria*, *Staphylococcus*, non-hemolytic *Streptococcus* and *Bacillus* spp.<sup>16</sup> Common pathogens include gram-negative bacteria and yeast. Many commercial diets contain nonpathogenic brewer's yeast that can be seen on Gram's stains of the crop or feces. Yeast that is contained in the diet should not be budding (an indication that the yeast is alive). Choanal cultures can be used to evaluate the microflora of the upper respiratory tract.

### Radiography

The anatomic differences of nestling birds must be considered when interpreting radiographs. The proventriculus and ventriculus are normally much larger than in an adult and may fill most of the abdominal cavity, especially if food is present. Intestinal loops may also be filled with food. Filling of the digestive tract with food reduces the volume of the air sacs. Growth plates in the bones may be open and the general muscle mass will be reduced.

### Endoscopy

The techniques and indications for endoscopy are similar to those for adults. An endoscope can be used to identify foreign bodies, inhaled food or aspergillosis in the trachea. Flexible or rigid endoscopes are useful for visualizing the crop when foreign bodies or burns are suspected. The proventriculus and ventriculus are best visualized with flexible scopes passed per os. Great care must be used when scoping the coelomic cavity of nestling birds because the relatively large digestive tract reduces the free space in which the scope can be safely introduced to the air sac. The bird should be fasted for several hours (depending on age) before attempting this procedure. Indications for laparoscopy include surgical sexing, documentation of aspiration or pneumonia and identification of abdominal or thoracic masses not confined to the digestive tract. Nestling birds can be endoscopically sexed as young as six weeks of age.

## Common Problems of Neonates

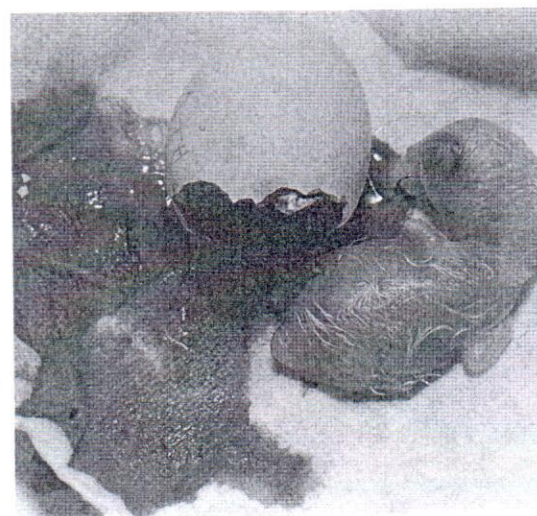
### Neonatal Problems

#### Perinatal Problems

Diagnosis, treatment and prevention of pre hatch, difficult hatch, unabsorbed yolk sac, rhage of the complexus muscle and other (mental problems associated with incubation hatching are described in Chapter 29. All problems may affect the growth and development of the chick (Figure 30.19).

#### Failure to Absorb the Yolk Sac

The yolk sac is a diverticulum of the intestine internalized into the abdomen just prior to hatch. Following hatch, the yolk is normally absorbed and provides nourishment and maternal antibodies during the first days of life. Once the yolk is absorbed, only a small remnant of scar tissue should remain. A common cause of death in artificially hatched chicks during the first week of life is retention of the yolk sac, which may be associated with primary (Color 30.2). Infections, improper incubation conditions and idiopathic causes can result in a failure of the yolk sac to be absorbed. In a retrospective study of 59 yolk sac cultures at the Denver Zoological Garden, *E. coli*, *Proteus*, *Streptococcus fecalis*, and



**FIG 30.19** A healthy, vibrant neonate should hatch. The pipping muscle (arrow) located on the dorsal coelom should not be misinterpreted as an abnormal swelling.



*ridium* sp. were the most common bacterial isolates associated with yolk-related problems.<sup>6</sup> In pigeons, there is an increased occurrence of omphalitis and bacterial septicemia in eggs that are washed prior to incubation.

Yolk sac infections can occur secondary to infections of the navel if it is poorly internalized prior to hatching. Alternatively, bacteria can multiply in the hatching egg following fecal contamination of the shell. In squab, omphalo-vitellitis may be caused by trichomonas. Affected animals have enormous yolk sacs that are 20 to 40% of the total body weight. The navel may be thickened, prominent and necrotic. Failure of yolk absorption is reported primarily in ratite and waterfowl chicks, but also occurs in companion birds. The normal interval for complete absorption of the yolk varies in different species. Precocial young use the yolk more quickly than altricial neonates. The yolk sac is no longer visible at six days in macaws, is absent in the ostrich in eight or more days and is palpable in emus for approximately seven days. Birds with unabsorbed yolk will have enlarged, doughy abdomens, and the large yolk sac may be visible through the abdominal wall or via radiography (Color 30.10). Dyspnea, exercise intolerance, depression, anorexia and inability to stand have also been reported.<sup>6</sup>

A surgical procedure has been described for removing the yolk sac in ratites and waterfowl.<sup>6</sup> The yolk sac is exteriorized and the yolk stalk and associated vessels ligated close to the jejunal/ileal junction of the small intestine. The body wall and skin are closed in separate layers (see Chapter 48).

### Critical Care of the Neonate

Nestling birds have little reserve capacity and sick neonates are often presented in critical condition, regardless of the underlying cause. Ill or abandoned nestlings are frequently hypothermic, dehydrated, hypoglycemic and may be septicemic. Supportive care to correct these physiologic imbalances should be implemented immediately (Table 30.6).

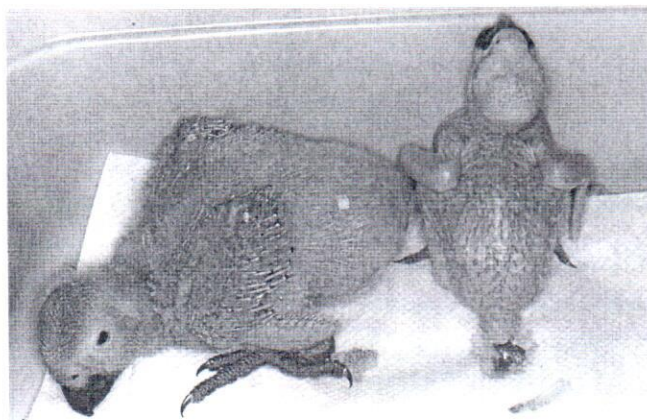
### Stunted Growth

Poor development and stunted growth is a common problem in both parent and hand-fed birds. Any factor that interferes with the homeostasis of the chick can alter growth (Figure 30.20). The leading causes of stunting are suspected to be underfeeding, chronic microbial infections and polyomavirus. Other possible causes of stunting include:

TABLE 30.6 Critical Care of the Neonate

1. **Collect samples for diagnostic blood work** and microbiology if this will not compromise the patient.
2. **Correct hypothermia.** Hypothermic neonates may be unresponsive and appear dead. They should be gradually warmed in an incubator set at 92°-95°F and monitored to make sure they do not become hyperthermic. The response to warming can be quite dramatic.
3. **Correct dehydration.** Dehydrated chicks will have sunken facial features, dry, reddened, wrinkled skin and feel sticky to the touch. The preferred route of fluid administration depends on the condition and size of the chick. If the chick is severely depressed and potentially hypovolemic, intravenous lactated Ringer's solution can be given by slow bolus administration at a rate of 10-15 ml/kg. An alternative to IV administration is to place an intraosseous catheter in the tibia using a butterfly catheter for small birds and an indwelling catheter for large ones.<sup>19</sup> If a catheter is used, the fluid deficit plus maintenance (40-60 ml/kg/day) should be replaced in a 48-hour period. Once the hypovolemia is corrected, subcutaneous fluids can be administered between the shoulder blades and into the groin. Lactated Ringer's solution, with or without added dextrose, is the preferred fluid because the lactate will provide some buffering of the metabolic acidosis assumed to occur in most dehydrated birds. Oral fluids can be used in birds that are responsive and are not having problems with crop stasis or regurgitation. Solutions containing dilute complex carbohydrates and electrolytes work best. Jarred baby cereal containing oatmeal, applesauce and bananas diluted 50 percent with water, the juice of boiled rice or commercial human infant fluid replacers have been successfully used as oral fluids.
4. **Correct hypoglycemia.** Chicks that have not been fed and those suffering crop stasis may be marginally hypoglycemic. Psittacine birds rarely seizure because of hypoglycemia; the most common clinical sign is depression. A solution of 2.5-5% dextrose can be added to IV fluids once the hypovolemia has been corrected. Dextrose should not be added to the fluids of a dehydrated neonate to prevent the induction of metabolic acidosis and the movement of fluids out of the intracellular space causing more severe dehydration. Glucose can also be added to oral rehydration fluids.
5. **Treat the septicemia.** Primary and secondary bacterial infections are very common in nestling birds. If suspected, treatment should begin immediately, because waiting for cultures may be fatal. If the bird is severely depressed or has crop stasis, parenteral antibiotics should be administered via the SC or IM route. They can also be added to IV fluids. The advanced generation penicillins (eg, piperacillin) and cephalosporins (eg, cefotaxime and ceftiofur) have excellent gram-negative activity and are relatively nontoxic. To avoid renal toxicity, the aminoglycosides should not be used in dehydrated patients. If the bird is capable of taking oral antibiotics, enrofloxacin or trimethoprim-sulfa provide good gram-negative bacterial activity. Enrofloxacin has been safely used in many nurseries but should still be used with caution in growing birds because joint abnormalities have been reported in mammals. Trimethoprim-sulfa combinations can cause regurgitation in some birds, especially macaws. Nystatin can be used to treat yeast infections of the alimentary tract (see Chapter 18).





**FIG 30.20** The African Grey Parrot (left) and Blue and Gold Macaw chick are approximately the same age. The birds were fed the same diet, which had been used successfully in many other macaw chicks. The cause of stunting in this macaw chick could not be determined. Note the large head compared to the rest of the body.

- Improper feeding: unbalanced nutrition, not feeding enough volume, not feeding frequently enough and feeding a diet with low total solids.
- Poor environmental conditions in early development: low or high temperature, low humidity.
- Diseases: any disease may cause a chick to expend energy fighting the disease, rather than using energy for growth. Clinical and subclinical microbial diseases caused by gram-negative bacteria and yeast are commonly implicated. These organisms may be secondary problems indicating primary viral infections, environmental inadequacies, immunosuppression or malnutrition. Stunted birds may also be infected with polyomavirus or PBFD virus.

### CLINICAL APPLICATIONS

Clinical signs of a sick, stunted chick include:

- Subnormal weight gain.
- Reduced muscle mass and subcutaneous fat deposits — thin toes, elbows and hips.
- Mal-proportioned body — head large in proportion to the rest of the body.
- Feather problems: delayed feathering in particular areas, a spiral pattern to the feathers on the back of the head, a "mohawk" pattern in macaw head feathers and excessive numbers of stress marks.
- Chronic, recurrent, microbial infections.
- General illness, including sluggish behavior, dehydration and pale skin color.
- Constant vocalization and begging for food.
- Failure of the palpebral slit to open at the normal time.

- Hyacinth Macaw, Palm Cockatoo and Queen Bavaria Conure neonates appear to have a high incidence of stunting than other species, possibly because they have dietary requirements that are not met with commonly used diets. Current evidence suggests these species do best when fed high-fiber, high-formulated diets throughout development, with the addition of nuts at weaning.

Malnourished birds can often be salvaged by correcting the underlying problems and gradually increasing their plane of nutrition. If the stunting is moderate and the cause is corrected early, many birds will wean normally. Moderate stunting may result in a smaller bird with a globose head and slender beak. If the stunting is severe, the bird may survive for a long time without growing but will eventually die. Euthanasia should be considered for nestlings that are confirmed positive for PBFD virus.

### Congenital Abnormalities

Congenital abnormalities have been infrequently reported in psittacine chicks. The lack of documented congenital abnormalities could be a result of underreporting, rapid death in embryos with abnormalities or undiagnosed congenital abnormalities in domesticated neonates. Additionally, the fact that psittacine birds have been domesticated only recently (and thus show a relatively low level of inbreeding) may result in reduced expression of genes responsible for congenital abnormalities. If the latter were true, one would expect a higher incidence of abnormalities in budgerigars and cockatiels, which have been domesticated longer than other psittacine birds. Reports in the literature would suggest that budgerigars, cockatiels and African Grey Parrots have a greater incidence of congenital deformities than do other psittacine species.<sup>2,5,20</sup> However, this apparent propensity for genetic malformation may simply represent a higher prevalence of these birds in captivity.

Documented cases of congenital abnormalities in psittacine chicks include bilateral anophthalmia in budgerigars,<sup>2</sup> varying degrees of cryptophthalmus and ankyloblepharon in four cockatiels,<sup>5</sup> congenital intra-hepatic biliary cysts in an African Grey Parrot and familial cataracts in Scarlet Macaws.<sup>24</sup> Skeletal deformities are considered to be the most common congenital abnormalities in psittacine birds,<sup>32</sup> but specific cases rarely have been reported in the literature. Other reported, but poorly documented, deformities include hydrocephalus,<sup>25</sup> and abnormalities of the pelvis, hock, feet, sternum and jaw,<sup>2</sup> stifle and hips,<sup>2,3</sup> tarsus,<sup>3</sup> long bones of the legs<sup>1</sup> and the beak.



congenital extra-hepatic biliary cyst in an African Grey Parrot was diagnosed by postmortem examination. The neonate was presented with a history of abdominal enlargement since hatch. Radiography and ultrasound indicated marked hepatomegaly.<sup>26</sup> Choanal atresia was diagnosed in an African Grey parrot and an Umbrella Cockatoo with histories of chronic (four months and four years, respectively) ocular nasal discharge since hatch. The absence of communication between the sinus passages and glottis was confirmed by endoscopy and positive contrast sinograms (see Figure 12.42).<sup>20</sup>

## Infectious Diseases

### Microbial Infections

Microbial infections of the alimentary and respiratory tract are among the most common problems seen in nestling psittacines and are diagnosed by examining Gram's-stained smears and culturing the crop, oropharynx or cloaca. The interpretation of culture results in nestling birds is controversial. Strains of *E. coli*, *Klebsiella* and *Enterobacter* spp. vary widely in pathogenicity; many cause disease, but some strains can be isolated from completely normal chicks. Some veterinarians believe that gram-negative bacteria and yeast should be treated only if a nestling is showing clinical signs of disease with or without an elevated white blood cell count. Other veterinarians believe all gram-negative bacteria and yeast are potential pathogens and should always be eliminated with antimicrobial therapy. The authors' personal opinion lies in the middle. If only a few organisms are cultured in a healthy nestling, treatment should be delayed unless clinical signs are evident. Mild microbial infections that are asymptomatic at one stage of growth may become symptomatic if the bird is stressed. Infections may be asymptomatic during the growth phase but become symptomatic during the stress of weaning. Because psittacine chicks are relatively easy to medicate prior to weaning, it may be prudent to treat and eliminate mild infections during the growth phase, especially if the hand-feeder is less experienced.

Treatment of microbial infections in nestling birds could be approached in the same manner as in adults (see Chapter 17), with a few special considerations. Medication is more easily delivered via the oral route because nestling birds are fed and handled frequently. If possible, antibiotics should be administered when the alimentary tract is relatively empty. Food in the alimentary tract reduces the absorption of most antibiotics, and calcium in the diet will sig-

TABLE 30.7 Procedures During a Nursery Disease Outbreak

- 1. Plan ahead:** Aviculturists should have a plan before an outbreak occurs. As explained below, at least three separate nursery rooms will be required in a disease outbreak. Friends and families can sometimes be enlisted to take birds into their homes and feed them, but it is best if they are trained before they are actually needed.
- 2. Isolate clinically ill birds:** At the first signs of illness, a chick should be isolated in a separate room, preferably one with air flow that is separate from the main nursery. Some aviculturists will question why isolation is necessary because the sick bird has already exposed the rest of the nursery to the disease. Sick birds should be immediately isolated because they shed higher quantities of infectious agents than asymptomatic carriers. Isolation of clinically ill birds can greatly reduce the load of infectious material in the nursery.
- 3. Do not bring new birds into the nursery:** New hatchlings should go to a separate nursery room to avoid exposure. Ideally, a separate caretaker would be available for these birds.
- 4. Maximize good hygiene practices:** If good hygiene practices are not in effect, they should be implemented immediately. Great care should be taken to reduce disease exposure when feeding chicks. If the same feeders must feed ill and healthy chicks, they should shower between groups and wear separate protective clothing in each room.
- 5. Determine the cause:** Polyomavirus is the most common cause of nursery outbreaks; PBFD virus, chlamydial, yeast and some bacterial infections can also spread rapidly through a nursery. In some cases, it is best to sacrifice and necropsy an ill nestling to rapidly determine the etiology of the disease problem. This may provide information that can save the other birds. Many microbial infections are secondary to diseases that are difficult to diagnose (such as polyomavirus, PBFD virus and chlamydia).
- 6. Treat the birds:** If microbial infections are identified, treatment should be initiated with appropriate drugs. If viral infections are identified, consider euthanasia or isolate sick birds and provide supportive care.
- 7. Eliminate the cause:** Find and treat or eliminate asymptomatic disease shedders. Investigate hygiene and feeding practices if microbial infections are confirmed.
- 8. Consider all-in all-out procedures:** Consider the primary nursery to be an isolation area. Do not add new birds until all nestlings that were exposed to the disease are moved to another area. This practice is essential with diseases with a long incubation or latency period (eg, polyomavirus and PBFD virus).
- 9. Decontaminate the environment:** During the outbreak, clean the facility, brooders and air control system frequently to decrease environmental contamination. At the end of the outbreak, thoroughly clean and disinfect the room before using it as a nursery. If polyomavirus or PBFD virus were encountered, pay particular attention to cleaning the air control system (see Chapter 32).
- 10. Do not sell chicks until proven healthy:** As noted above, many diseases (especially polyomavirus and PBFD virus) have a long incubation period. Some birds that are infected early in development will not show clinical signs until weaning. Ideally, neonates should not be sold until they are tested for these two viral diseases.



nificantly reduce the absorption of tetracyclines. However, some oral antibiotics cause local GI irritation (eg, trimethoprim/sulfonamide combinations and doxycycline), and birds will regurgitate unless the drug is administered with a small amount of food. A bird should not be fasted for antimicrobial administration if this will reduce the number of feedings and slow growth. If injectable drugs must be used, the subcutaneous route is preferred, because young nestling birds have little muscle mass and it is difficult (but not impossible) to deliver intramuscular injections. Injections should be carefully given into the pectoral muscle of young chicks, as the sternum is soft and easily penetrated with a needle. To prevent secondary yeast infections, neonates should be screened with fecal Gram's stains, or nystatin should be administered prophylactically. The source of the microbial infection and contributing causes such as malnutrition should be identified and eliminated.

### Viral Infections

Nestling birds are prone to viral infections that may be carried symptomatically or asymptotically by adult birds. These diseases are more completely described in Chapter 32; the salient points in nestlings are described in this section.

Polyomavirus is the most common viral infection described in psittacine nurseries. The onset of clinical signs is usually acute and includes crop stasis, listlessness, regurgitation and vomiting. Hemorrhages may be observed on the skin, and injection sites and broken or plucked feathers will bleed excessively (see Color 32). Most birds are nonresponsive to therapy and die within 24-48 hours. Survivors fail to gain normal weight, are prone to secondary microbial infections and often fail to wean. Feather abnormalities can occur that are grossly similar to those seen with PBFD virus infections. Epilation of all of the large flight feathers of the wings and tail has been observed in older cockatoos. Mortality in the nursery can be widespread or sporadic, depending on the immune status of the chicks and husbandry practices in the nursery. A more common and subtle clinical presentation has been identified. Slow growth, abnormal flora (gram-negative and yeast), beak malalign-

ment, leg deformities and hepatomegaly may be the only clinical signs present (Harrison GJ, unpublished).

Polyomavirus can be controlled in an aviary by testing adult birds and raising neonates from carriers separately from neonates from non-carriers. Neonates can be tested as they are pulled from the nest to determine if they are shedding polyomavirus. Shedders should be raised separately from non-shedders.

Psittacine beak and feather disease also occurs in neonates (see Color 32). Cockatoos and African Grey Parrots are most commonly affected. Clinical signs are most often seen in older, fully feathered chicks just prior or at the time of weaning (Figure 30.21). The onset is subacute and clinical signs include weight loss, listlessness and feather abnormalities. Many neonates showing clinical signs will have reduced red and white blood cell counts. For example, an affected African Grey Parrot with severe bone marrow necrosis had a total white blood cell count of 2000 and a PCV of 4. Idiosyncratic syndromes are seen in some species; loss of only the tail feathers has been observed in *Poicephalus* spp. and lorries. The course of disease is often chronic. PBFD virus can be eliminated from a collection by testing adult birds and removing those that are subclinically infected.



**FIG 30.21** A group of 14 African Grey Parrots developed PBFD after being exposed to the virus by a hand-feeder who worked in a pet shop where a PBFD virus-infected bird was housed. The neonates were of varied age when exposed to the virus and had different gross presentations of the disease. The two chicks on the right were clutchmates that were about ten days old when exposure to the virus was suspected to have occurred. In these chicks most of the tail, flight and body feathers were affected. The chick on the left was about five weeks old when exposure occurred, and in this bird, only a few of the flight and tail feathers were initially involved. All of the birds were confirmed to have PBFD virus by immunoperoxidase staining of feather biopsies and by DNA probe detection of PBFD virus nucleic acid in circulating white blood cells. This outbreak indicates the varied clinical signs that occur with PBFD virus infections depending on the age of the bird when virus exposure occurs. It also emphasizes the danger in having individuals that are exposed to other birds (those outside of the closed nursery) having contact with neonates.



any neonate that is transferred from a facility should be tested negative before shipment. This will protect the aviculturist from allegations that they sold a subclinically infected bird.

Other viral infections are rarely reported in nestling birds. Herpesvirus infection (Pacheco's disease) occasionally causes nursery outbreaks. Poxvirus occurs primarily in lovebirds and imported South American psittacines such as Amazon and *Pionus* parrots. Poxvirus outbreaks may occur in tropical regions (eg, southern Florida) with high bird and mosquito populations (Harrison GJ, unpublished). Poxvirus is also common in free-ranging passerine birds and Columbiformes. The clinical signs and management are similar to those in adults (see Chapter 32).

Diseases of suspected viral etiology are occasionally observed in pediatric patients. Neuropathic gastric dilatation has been described in birds of all ages. Care should be taken when interpreting juvenile bird radiographs since the proventriculus is normally larger than in adults. Avian viral serositis is a neonatal problem characterized by the accumulation of serous fluid in the abdominal cavity (see Color 32).<sup>19</sup> Large amounts of fluid may accumulate and cause severe abdominal distension. Liver, bursal and lymphoid necrosis may also occur. This problem has been suspected to be caused by a togavirus that is related to eastern equine encephalomyelitis virus.

### Parasitic Infections

With a few exceptions, internal parasites are an infrequent cause of disease in nestling psittacines in the United States, but are commonly found in countries where parrots are raised in flights with dirt floors. They are also found in finches, zoological avian species and free-ranging birds. *Trichomonas* and *giardia* are frequent causes of death in young budgerigars, cockatiels, finches and Columbiformes. *Coccidia* are commonly recovered from lorikeets, lorikeets, passerines, Columbiformes, and finches; their importance appears to depend on the chick's immune status. *Atoxoplasma serini* is a common cause of mortality in juvenile canaries. The safety of many parasitocidal drugs has not been investigated in nestling birds, and care should be exercised when selecting a treatment regimen. For example, furacin has a low therapeutic index in lory neonates (see Chapter 37).

## Disorders of the Alimentary Tract

### Pharyngeal and Esophageal Trauma

Damage to the pharyngeal or esophageal wall can occur during metal tube- or syringe-feeding when a nestling lunges against the feeding instrument. This can be prevented by being careful or by use of a soft crop tube when administering food to birds with a strong feeding response, such as macaws. When a puncture occurs, food may be deposited into the subcutaneous tissues and will often migrate caudal to the puncture site (Color 30.8). Liquid food can drain all the way to the base of the crop and be confused with crop contents. If the puncture is in the pharyngeal cavity, food will usually collect in the space ventral to the mandibles. Extravasated food causes a massive inflammatory response and should be treated aggressively and quickly. The bird should be stabilized, and the food pockets surgically opened, curetted and thoroughly flushed (see Chapter 41). Antimicrobial therapy designed for both gram-positive and gram-negative organisms should continue for at least 14 days.

### Air in the Crop

Bubbles or filling of the crop with air is usually caused by aerophagia. It occurs most often in stunted birds that beg constantly for food, but has also been observed in young birds of many species (especially cockatiels). Slowly delivering food will contribute to aerophagia because the chick attempts to gulp the feeding formula faster than the food is provided. Some inexperienced hand-feeders will confuse this condition with crop stasis, subcutaneous emphysema and filling of the cervicocephalic air sac. Air is easily distinguished from food or fluid by transilluminating the crop. Visualization of blood vessels in the crop wall can help differentiate between air located in the crop and air located in the subcutaneous space.

Severe aerophagia decreases the amount of food the bird can consume and may contribute to stunted growth. Feeding a nutritious formula at a steady rate will correct the problem in some birds. If aerophagia is persistent, the ingested air can be carefully removed ("burped out") and the bird immediately fed before it can gulp more air. In some cases it may be necessary to tube-feed these neonates.

### Crop Stasis

Failure of the crop to empty normally is a common sign of illness in nestling birds. The problem is usually related to generalized gut stasis (often caused by a yeast or gram-negative bacterial infection) rather



than a primary crop disorder, but there are numerous possible etiologies. Food that remains in the crop will ferment and have a sour odor — hence the lay term “sour crop” (Color 30.14).

Causes of crop stasis include:

- Primary crop disorders: foreign bodies, crop infections; crop atony caused by overstretching; crop burns; crop impactions caused by fibrous food, large food chunks (eg, raw carrots) or bedding; and dehydration of food in the crop leading to formation of a concretion or doughy mass.
- Delayed transit time or obstruction of the distal gut: intestinal ileus due to generalized infection, neuropathic gastric dilatation, polyomavirus, GI foreign bodies or hypothermia.
- Cold food.

The motility of a normally functioning crop that is free of infectious agents should not be altered by the consistency of the food. The crop should be examined and gently palpated to determine if it is atonic or burned, or if foreign material or an impaction is present. A CBC, serum chemistries, cloacal culture and radiographs are indicated if the bird has clinical signs of disease. Whole body radiographs can be used to evaluate the distal alimentary tract and barium contrast studies can be used to determine gastrointestinal transit time. The crop can be swabbed or flushed for culture and cytology.

A bird with crop-emptying problems should be fed carefully. The crop should not be overstretched, as this will cause atony and compound the problem. Mild cases of crop stasis caused by a dehydrated food mass or overfeeding can often be solved by administering a small amount of warm water and gently massaging the crop. If the food does not pass in three to five hours, the crop should be emptied and flushed with warm saline. This removes the old food, which acts as a growth media for microbial proliferation. To flush the crop, a lubricated soft feeding tube with an open end is gently passed into the crop, and a small amount of saline is flushed in and out to draw crop material into the syringe. It may be necessary to palpate the tube and direct it toward the food mass and away from the crop wall. When moving or withdrawing the tube, negative pressure on the syringe should be released to make sure the tube does not attach to the crop wall and cause damage. The removal procedure should be accomplished in stages if the bird becomes overly stressed.

Crop stasis caused by generalized ileus is a serious problem that requires immediate attention. Complete stasis may be one of the early signs associated with fatal diseases such as polyomavirus, PBFI virus, septicemia or sarcocystis infection. With the progressive diseases, treatment may not be successful. If the stasis is caused by a microbial infection (yeast, bacteria or chlamydia), intensive medical management may be effective. Treatment consists of antimicrobial therapy targeting the etiologic agent, correcting the dehydration and malnutrition that result from stasis and providing a complex carbohydrate diet to provide energy and gently re-stimulate gastrointestinal motility (Table 30.8).

### Crop Burns and Fistulas

Crop burns can occur when excessively heated food is fed or if a bird contacts a heating pad or hot liquid. Severe burns can result from a single, overly heated meal (eg, greater than 120°F), or by repeated exposure to food that is slightly hot (115°F). Birds readily accept hot food, and the feeder may not realize a problem for days to weeks after the burn occurs. If one bird in a nursery has a crop burn, all the other neonates should be carefully examined to determine if they have also sustained injuries.

The method of treatment depends on the degree of tissue damage and stage of healing. Mild burns result in tissue swelling, erythema and blister formation, and can be treated with antibiotics and topical application of soothing vitamin A and E ointment (Color 30.11, 30.12). The bird should be fed reduced volumes more frequently during the healing process.

Severe crop burns cause greater tissue damage. In the early stages the crop will adhere to the overlying skin; the skin will be hyperemic and the site may be covered with a scab. Eventually the crop may fester, and food and water will leak from the opening, soiling the bird's chest. Bird owners are frequently puzzled by this odd phenomenon. Crop fistulas are treated by removing the scab, surgically excising the necrotic portion of the skin and crop and then suturing and individually closing the crop and skin (Chapter 41) (Color 30.12). The timing of surgery is important. Birds with this condition are often debilitated and should receive supportive care and enteral alimentation to build their strength prior to anesthesia and surgery. Ideally, the tissues surrounding the fistula should be given as much time as possible to heal before surgery, and the scab should be left in place as long as possible to encourage wound contraction that will reduce the size of the fistula (C



TABLE 30.8 Treatment for Crop Stasis

1. Empty and flush the crop with LRS using a feeding tube. Repeat every six to twelve hours if the crop does not empty. Digestive enzymes are often beneficial.
2. Give intravenous, intraosseous or subcutaneous fluids. Most birds with crop stasis are dehydrated and require parenteral fluid administration. A Gram's stain of a crop swab can be used to determine the microbial agents that are present.
3. If a generalized microbial infection is suspected, start treatment with a broad-spectrum antibiotic and antifungal drug. Cephalosporins and penicillins are the safest drugs to use; aminoglycosides and sulfas should be avoided due to potential dehydration and renal toxicity. Injectable antibiotics should be used if there is severe stasis because oral antibiotics would not be properly absorbed. Oral antifungals (nystatin) should be used because the parenteral antifungal drugs (eg, amphotericin B) may be toxic. If chlamydiosis is diagnosed, a single SC injection of oxytetracycline or doxycycline IV can be used to initiate therapy, followed by oral doxycycline (see Chapter 17).
4. If the bird has generalized ileus, a motility stimulant such as metoclopramide or D-panthenol can be administered. Response to these stimulants is highly variable.
5. Once the crop starts to partially empty and the bird is stabilized, limited feeding should resume. The bird should be fed a liquid, complex carbohydrate, medium-fiber-content diet until the crop is emptying normally (see Chapter 15). Gerber's oatmeal with applesauce and bananas baby cereal mixed 50:50 by volume with water works well. The bird should be fed less volume, more frequently. As the crop starts to empty normally, the diet that is normally fed should be gradually substituted (provided it is nutritionally adequate). It is important to restore normal feeding as quickly as possible because dilute baby food diets do not provide sufficient nutrition for growth. Subcutaneous fluid administration and antibiotics should continue until the bird is clinically normal.
6. If the crop is overstretched or atonic it is beneficial to apply a "bra" to elevate the crop and facilitate emptying (Figure 30.22). The bra can be constructed from elastic bandage material or baby tube socks and should be applied while the crop is full to make sure it is not too tight. The neonate should be confined to a small container for a few days if it objects to the bra and falls over backwards. Most chicks will eventually accept the bra.
7. Parenteral nutrition would be beneficial in cases of crop stasis; however, at the time of this publication this is still a highly experimental procedure and specific recommendations are speculative at best (see Chapter 15).

.12). If surgery is attempted before the tissues surrounding the burn have healed, it is difficult to accurately assess the extent of devitalized tissue that must be debrided. Surgical adhesives can be used to close the crop and allow feeding or a pharyngotomy tube can be passed (see Chapter 41). It has been estimated that it takes seven to ten days following a burn to determine the extent of tissue injury.<sup>8</sup>

Large crop defects (greater than one-third the size of the crop) can be difficult to repair. Closure frequently

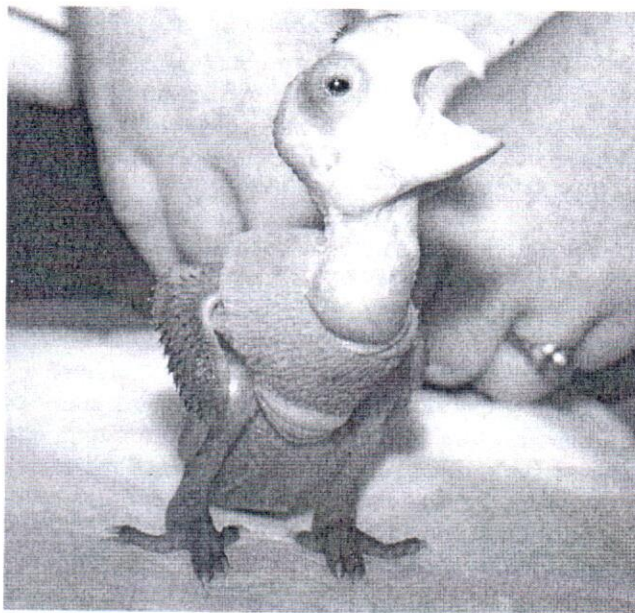


FIG 30.22 In an overstretched, pendulous crop, the distended crop hangs over the thoracic inlet where food cannot enter the thoracic portion of the esophagus. A crop bra can be used to elevate the crop and increase the gravitational forces that encourage food to pass through the thoracic portion of the esophagus and into the proventriculus (courtesy of Kim Joyner).

results in a reduced crop capacity. Following repair, the bird should be fed small amounts of food frequently to prevent reflux and aspiration. The amount of food offered can be gradually increased to stretch the crop. If the esophagus was involved, a pharyngotomy tube may be necessary to allow feeding yet protect the wound during healing. An alternative to a pharyngotomy tube is to place a mushroom-tipped jejunal catheter in the crop and tunnel it subcutaneously up the side of the neck. If it is impossible to close the skin over the defect, the wound should be covered with a permeable dressing and allowed to heal as an open wound.

### Regurgitation

Hand-fed birds (especially macaws and African Grey Parrots) commonly regurgitate at weaning, and it is important to differentiate this relatively normal phenomena from a pathologic condition. Causes of regurgitation include overfeeding, crop stasis, alimentary tract infections (especially candidiasis), alimentary tract foreign bodies, blockage of the alimentary tract and use of some drugs such as trimethoprim-sulfa compounds and doxycycline. Treatment consists of correcting the underlying cause.



### Foreign Body Ingestion or Impaction

Nestling birds are curious and may ingest foreign objects. Preventing neonates from consuming foreign bodies is far easier than treating them. The feeder should be very selective about the objects the birds are allowed to contact (Color 30.9).

If a consumed foreign object is located in the crop, the bird should be treated immediately to prevent the object from entering the proventriculus. It is much easier to retrieve objects from the crop than the proventriculus, and birds have a remarkable capacity for passing even relatively huge objects such as feeding catheters into the proventriculus. Some objects can be "milked" up the esophagus and retrieved from the caudal oral cavity with forceps. Forceps can also be introduced into the crop to retrieve foreign bodies, with or without the aid of endoscopy. Objects can also be retrieved via an ingluviotomy incision (see Chapter 41).

Objects in the proventriculus or ventriculus can be tolerated for long periods<sup>8</sup> but should be retrieved if they have the potential to erode the stomach wall or can be digested, resulting in toxicity. Foreign bodies may be removed using an endoscope, or forceps can be passed into the proventriculus via an ingluviotomy incision with the aid of air insufflation (via a rubber catheter) (see Chapters 13, 15). The endoscope must be carefully passed to prevent rupture of the thoracic esophagus or proventricular wall.<sup>8</sup> The proventriculus and ventriculus can also be opened surgically as described for adult birds (see Chapter 41).

Proventricular or ventricular impactions caused by grit or bedding material are serious and require urgent attention.<sup>8</sup> Mild accumulation of material in the ventriculus (that does not impede passage of ingesta) can be treated by hydrating the patient and administering laxatives (dioctyl sodium sulfosuccinate or psyllium or digestive enzymes). Psyllium should be limited to no more than one percent of the dry weight of the tubed formula to prevent it from causing an impaction. If this does not work, mineral oil should be administered into the crop, followed 30 minutes later by a large volume of barium sulfate (10 to 15 ml/kg) that may help force the mineral oil through the GI tract by gravitational pressure. The patient should be kept well hydrated with SC fluids due to the hygroscopic nature of barium sulfate. Serial radiographs can be used to evaluate the success of the therapy. If this treatment fails, proventriculotomy (see Chapter 41) or gastric lavage (see Chapters

13,15) can be attempted but are associated with a guarded prognosis.

### Intestinal Intussusception

This condition is occasionally reported in macaws and is associated with diarrhea and possibly intestinal hypermotility.<sup>15</sup> In severe cases the ileum may telescope into the colon and protrude through the cloaca. Mild cases are diagnosed radiographically and may respond to antimicrobial and supportive therapy. Severe cases with a visible cloacal prolapse are usually fatal.<sup>8,15</sup> Successful jejunostomy and jejunocloacal anastomosis has been reported.<sup>35</sup>

## Disorders of the Respiratory Tract

### Upper Respiratory Infections

Nestling birds can pass food through the choanal slit, resulting in clogged nostrils and upper respiratory problems. These can be treated by removing the food plug with a feathered wooden applicator (see Chapter 8) or dull needle, and gently flushing the nares with saline until clear. Microbial infections of the upper respiratory tract are treated in the same manner as in adult birds (see Chapter 22).

### Aspiration Pneumonia

Birds may aspirate food during feeding or following regurgitation. Aspiration occurs most often in birds that are reluctant to feed or if the aviculturist introduces food when there is no feeding response. If large amounts of food are inhaled, the bird will die from asphyxiation (see Color 22). Rapid placement of an air sac cannula and aggressive antimicrobial (eg, trimethoprim-sulfa, ketoconazole) and steroid therapy may save the patient, but the prognosis is poor. Some birds respond to such aggressive treatment and die months later due to a chronic fungal infection. If small amounts of food are aspirated, the event may not be noted at the time but the bird may later develop a foreign body pneumonia. An affected bird will show poor weight gain, a persistently elevated white blood cell count and may or may not show respiratory signs. Often, the pneumonia may be noted only by radiology or at necropsy.

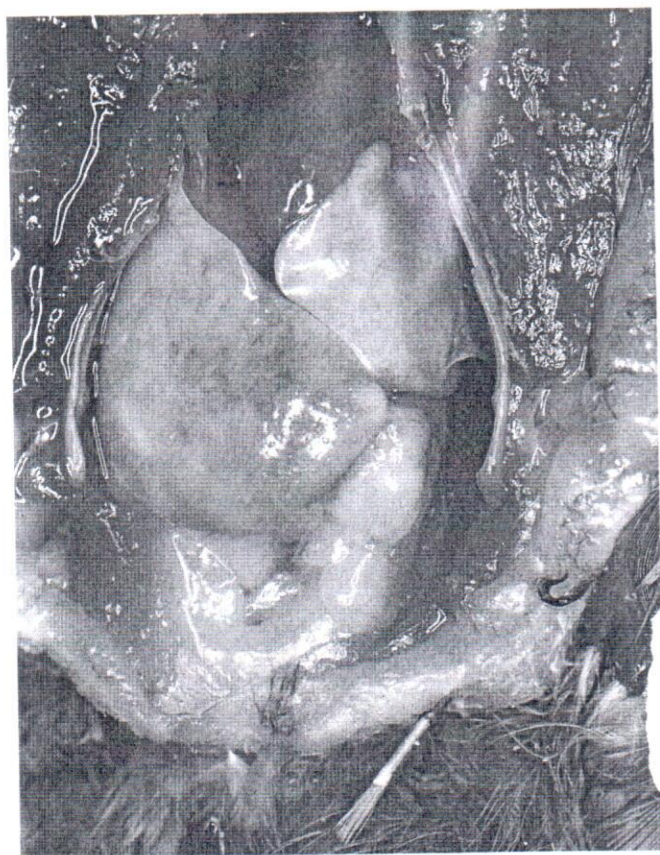## Miscellaneous Disorders

### Hepatic Lipidosis

In most cases, hand-fed birds gain weight slower than parent-fed birds, and the hand-feeder should be instructed to maintain the maximum weight gain possible. Umbrella Cockatoos, Moluccan Cockatoos



and Blue and Gold Macaws may be an exception to this recommendation. In these species, and possibly others, it is possible to overfeed (especially in the later development stages) and cause massive weight gains and hepatic lipidosis. It has been suggested that multiple deficiencies of fiber, vitamins and minerals and nutritional excesses combine to cause this problem (Harrison GJ, unpublished). Affected birds are usually dyspneic, especially when food in the digestive tract places additional pressure on the respiratory system following feeding (Figure 30.23). The abdomen is usually protuberant and the pale, enlarged liver may be visible through the skin. In these cases, the amount of food fed should be *gradually* reduced and small meals should be fed more often to avoid respiratory distress. Hyperthermia will aggravate the respiratory distress and should be avoided. If identified early, the birds may wean normally, but



**FIG 30.23** A six-week-old Blue and Gold Macaw was presented for a swollen, fluid-filled abdomen and severe dyspnea. The bird was 30% heavier than normal when compared to standard weight charts. The neonate was being fed a homemade formula that consisted of a peanut butter base supplemented with numerous herbs and vitamins. The owners requested euthanasia. On post-mortem the bird had large accumulations of fat throughout the abdomen, and the liver was whitish-yellow with a roughened, irregular surface suggestive of hepatic lipidosis.

in severe cases the liver will be massively enlarged and the bird will die. This condition can be prevented by feeding a proven diet and comparing the bird's weight gain to establish growth charts. If the bird is normal in body size but substantially heavier than the upper limit on the chart, the possibility of hepatic lipidosis should be considered.

### Hepatomas

Hepatic hepatoma has been described primarily in macaws, and may occur when blunt trauma ruptures the liver and causes hemorrhage.<sup>15</sup> The trauma may occur when the bird is lifted with pressure over the liver or it may simply be idiopathic. Affected birds are pale with extremely low hematocrits and may be saved by repeated blood transfusions within the first few days following the traumatic event.

### Gout

Deposition of uric acid crystals in the tissues is called visceral gout and is usually due to end-stage renal disease. Clinical signs include crop stasis and vomiting followed by death. Excess vitamin D<sub>3</sub> results in dystrophic calcification of numerous organs including the kidney, which then may result in gout (see Chapters 3, 21). Macaws seem to be particularly sensitive to excessive dietary consumption of vitamin D<sub>3</sub> and calcium (see Color 21).<sup>33</sup>

### Wine-colored Urine

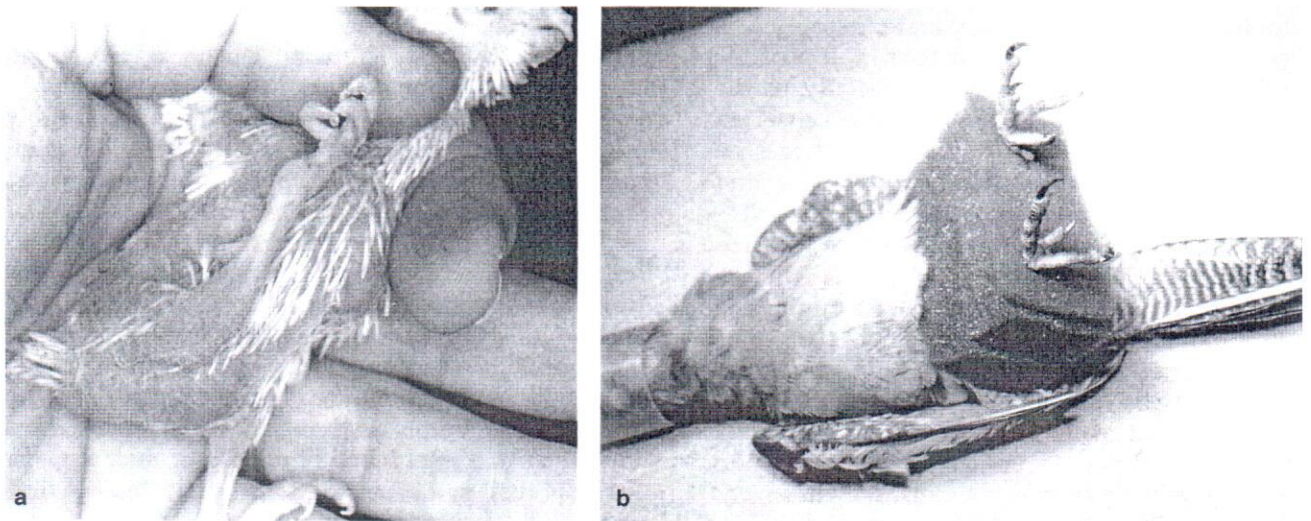
Reddish urine and urates have been described in juvenile African Grey Parrots and some Amazon and Pionus parrots. It can be distinguished from hematuria by a fecal occult blood test. It occurs sporadically with several hand-feeding formulas, and the pigment may be more pronounced on some bedding materials, especially certain brands of paper towels. This condition has not been associated with pathology or other clinical signs.

## Musculoskeletal Disorders

### Leg Deformities

Orthopedic problems in nestling birds are poorly understood and the causes are believed to be multifactorial. Nutritional deficiencies (especially of vitamin D<sub>3</sub> and calcium), trauma and housing the birds on slippery surfaces are the most common causes. Genetic and incubation abnormalities probably also occur. Polyomavirus may be a common underlying cause (Harrison GJ, unpublished). In general, leg deformities are challenging to repair and the earlier the diagnosis and the younger the bird, the better the prognosis<sup>8,15</sup> (see Chapter 42).





**FIG 30.24** a) The cause of splay leg in psittacine birds has not been confirmed. Suggested etiologies include nutritional deficiencies, tree poor footing, improper incubation and genetic defects. Severe deformities, like the one in this cockatiel chick, are difficult to treat with surgery. b) In mild cases that are treated early, splinting or foam rubber hobbles may be effective in correcting the lesion (courtesy of R Clipsham).

▪ **Spraddle or Splay Leg:** Birds with this condition will have one or both legs splayed laterally from the hip or stifle (Figure 30.24). Mild deformities can be treated by packing the bird in a deep cup with tissue or towel padding to take pressure off the legs. More severe deformities and those in older birds require a fixation device in addition to packing in a cup. The chick can be taped over a foam rubber pad or sanitary napkin, or placed in a piece of foam with slits cut for the legs. As an alternative, the legs can be hobbled together with elastic tape at the tarsometatarsus and if needed across the tibiotarsus. The hobble sites should be padded with cotton and care should be taken not to tape too tightly. The hobble should be changed every two to four days to allow growth. More severe deformities require more rigid fixation.<sup>8,15</sup> A suspension method of treating this condition has been reported.

▪ **Valgus Deformity** (Bowing of the tibiotarsus with lateral rotation of the femur or tibiotarsus): This is usually caused by premature closure of one side of the growth plate of the proximal or distal tibiotarsus. This causes uneven bone growth and bowing and twisting in the tibiotarsus (Color 30.6). It is a serious condition that may not respond to conservative treatment. Surgically closing the opposite side of the growth plate or periosteal stripping to even out the growth, followed by a dome osteotomy and realignment of the tibiotarsus may be necessary.<sup>15</sup> The osteotomy is repaired with a biplaner KE apparatus. The osteotomy is best performed after the bones have

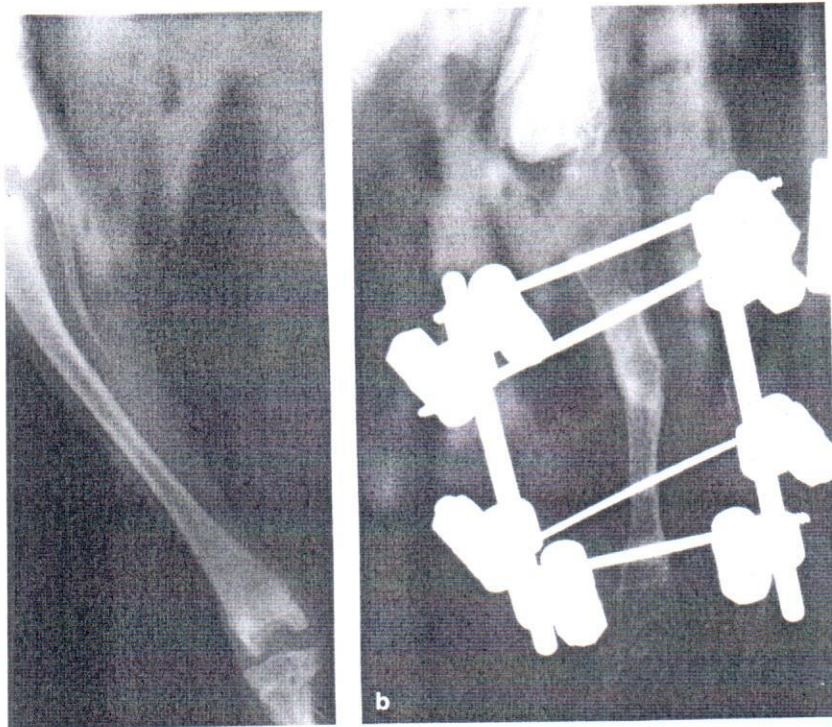
ossified (Figure 30.25). Macaws and cockatoos should be approximately 65-70 days old before attempting an osteotomy procedure.

#### Toe Malposition

Malposition of digits in neonatal birds is believed to be secondary to malnutrition. Reducing the dietary protein content and slowing the growth of splayed chicks may aid in correcting the problem.<sup>8</sup> Affected chicks should receive parenteral and dietary vitamins and mineral supplements including vitamins D<sub>3</sub>, E, B complex, C, K<sub>1</sub>, calcium, iodine, selenium, iron, copper and cobalt. Other proposed etiologies include virus infection and improper incubation.

Improving the substrate is also beneficial. The chick should be placed in a smaller, padded environment such as a teacup lined with a towel. This will diminish the tendency for the legs to splay and toes to curl. In some patients, this alone may be adequate to correct the condition without splinting. In many cases, taping the affected toes in a normal position is necessary. This condition develops quickly, often in a matter of hours, and when the toes are taped in a normal position, the condition is corrected quickly. Generally, the affected digits should be maintained in the supported position for approximately as long as they were malpositioned (usually a maximum of several days). If the condition is recognized early, corrective measures may be required for only a few hours. This must be monitored closely as deformities can be caused by leaving bandages or splints on





**0.25** a) An eight-week-old Moluccan Cockatoo was presented with a valgus deformity of the left tibiotarsus. Radiographs indicated bowing of the tibiotarsus starting in the middle third of the bone. b) The defect was repaired using a dome osteotomy that was stabilized with a bilateral KE apparatus. This radiograph was taken four weeks post-surgery. Note the stable bone union and minimal callus formation suggestive of primary bone healing. The stabilizing pins used in this bird were positive-profile threaded pins that provide maximum strength and tend to form a tight, long lasting pin/bone interface. All of the pins in this bird remained secure and had to be removed by "unscrewing" them from the bone.

g. Additionally, the developing circulatory system and muscle mass of neonates make them more susceptible to edema and pressure necrosis. Their skin is thin and sensitive, so all forms of external coaptation should be adequately padded.<sup>8</sup>

A corrective shoe may be made from a piece of firm material such as thin cardboard or radiographic film. The shoe should be made to properly fit the foot of the affected individual with a notch in the shoe into which each toenail will be placed. Once the shoe is made, the foot is placed in the shoe and each digit is held into a normal position using very thin strips of skinning tape. A hydroactive dressing may be used to make a corrective shoe. The material is cut to fit the foot as described above. The plantar aspect of each digit is placed on the sticky surface of the hydroactive dressing in a normal position. A second piece of hydroactive dressing is applied dorsally to sandwich the digits in place and to maintain reduction. This material is especially appropriate as it is soft, unlikely to cause pressure problems and easy to remove.

### Constricted Toe Syndrome

This condition is most commonly reported in Eclectus Parrots, macaws and African Grey Parrots. Any toe may be affected, but the distal phalanx of the outer digits (1 and 4) is most often reported. The lesion consists of an annular ring of constriction that eventually causes swelling and necrosis of the distal segment of the toe (Color 30.7). It appears similar to the lesion induced by wrapping a thread around the toe, but this is seldom the cause. The etiology is unknown but may be related to low brooder humidity<sup>22</sup> or fracture of the digits. Histology usually demonstrates edema and inflammation; microbial infections are rare except as secondary invaders. The condition can be corrected and the digit saved if identified early. If the degree of constriction and swelling of the distal segment is mild, warm water soaks and frequent massage may restore circulation and correct the condition. If a fibrous annular ring is present, it should be carefully incised and accumulated serum and tissue debris gently debrided (see Chapter 41). The toe should be

soaked in warm, dilute, povidone-iodine solution and bandaged. A DMSO dressing may reduce inflammation and antibiotic ointments help soften and prevent reformation of the annular ring. If the distal segment is severely swollen or necrotic it should be surgically removed, preferably at a joint proximal to the constricting lesion. Toe constrictions can often be prevented by keeping susceptible species on non-desiccating surfaces and in brooders where the humidity is maintained above 50%. Commercial forced air brooders with rapid air changes tend to desiccate the chicks and should be avoided.

### Stifle Subluxation

Stifle luxation or subluxation in both juvenile and adult birds has been reported.<sup>8</sup> This condition may occur when a bird gets a leg caught in the enclosure and struggles to free itself. Idiopathic luxation of the stifles may also occur and appear to be particularly common in cockatiels (Figure 30.26). Rigid fixation of the stifle by applying a KE apparatus to the distal femur and proximal tibiotarsus may fuse the joint



## Neonatology

### Color 30.1

Psittacine chicks are hatched basically naked with the exception of a sparse natal down. Neonates should be hatched in a warm brooder (94°F), and the feathers should dry shortly after hatching. This neonate exited the egg five minutes before this photograph was taken (courtesy of Apalachee River Aviary).

### Color 30.2

A Moluccan Cockatoo egg was presented for evaluation. The embryo internally pipped three days earlier than anticipated and died the day after entering the air cell. The embryo was hyperemic and the yolk sac had not started to absorb. The embryo weighed 32 g (the average weight for chicks from this pair was 22 g) and was considered to be large for the egg (fetal monster). Aerobic and anaerobic cultures of the yolk sac did not indicate the presence of bacteria. There was no histologic indication of abnormalities in any tissues.

### Color 30.3

Healthy neonates that are receiving proper care will be bright and alert and have full crops. Development is rapid in large psittacine chicks, like this five-week-old Umbrella Cockatoo. This neonate will grow from a hatching weight of 18 g to its adult size of 600 g in eight to ten weeks.

### Color 30.4

Healthy neonates should have yellowish-pink skin with a supple warm feel. Dehy-

drated nestlings like this Rose-breasted Cockatoo have dry, hyperemic skin that feels "sticky."

### Color 30.5

The normal liver of a recently hatched chick may appear large, pale yellow or light green. As the bird matures, the liver becomes a normal brownish-red color and assumes a more proportional size within the abdominal cavity.

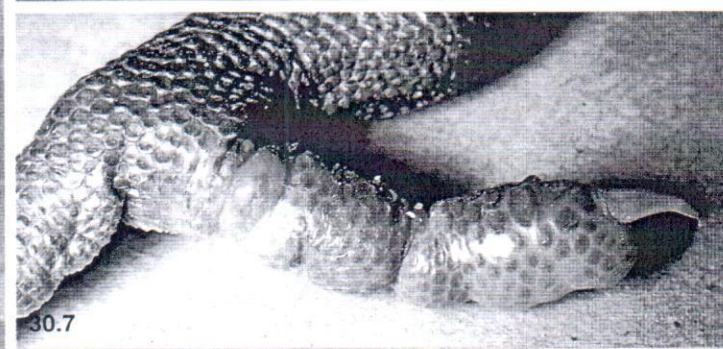
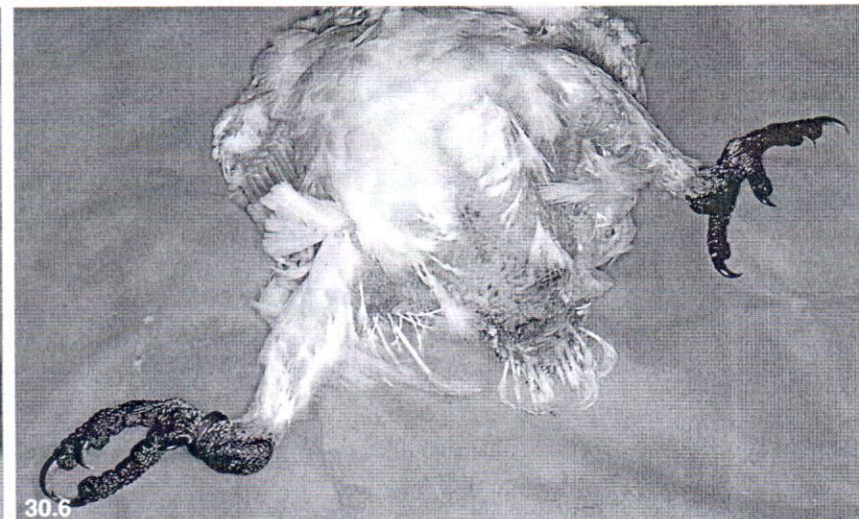
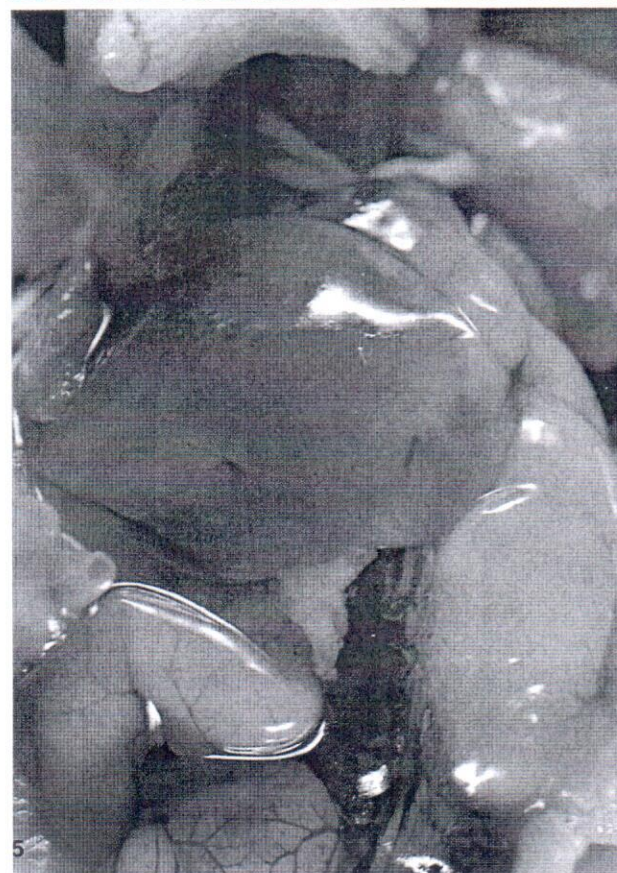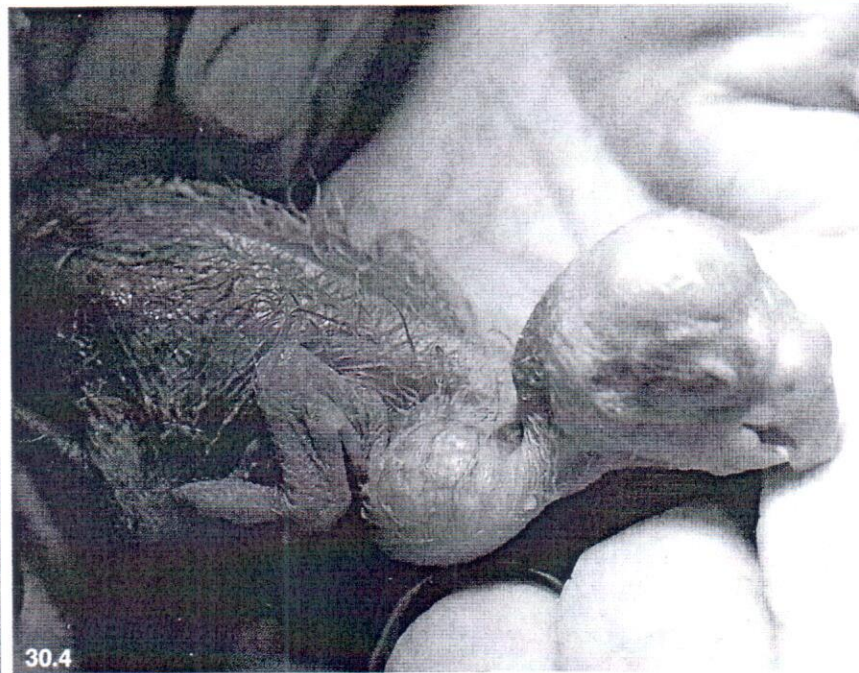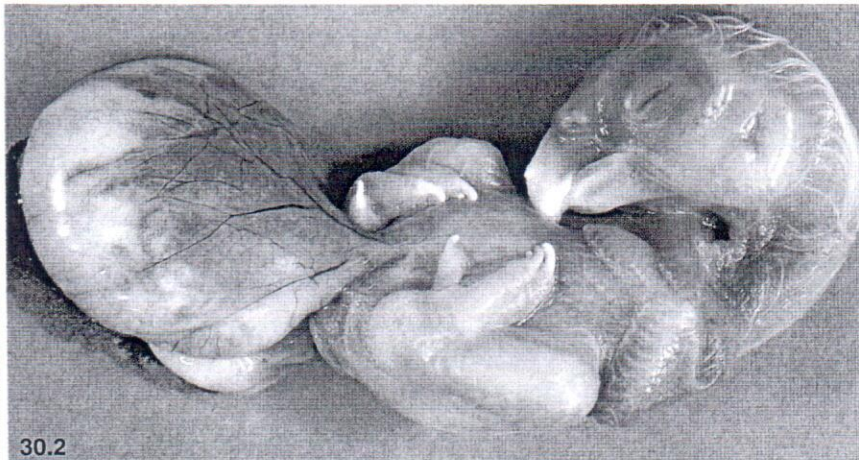
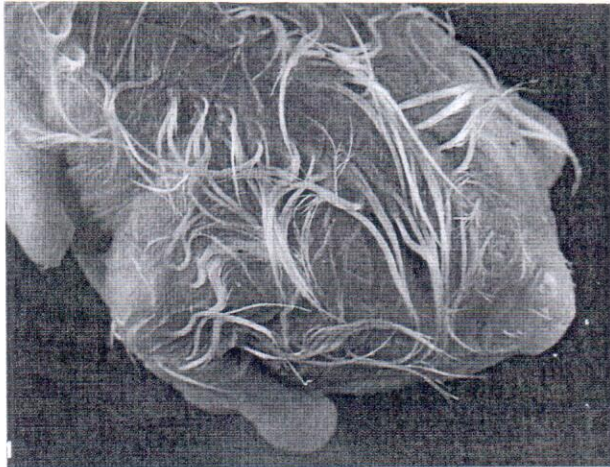
### Color 30.6

An eight-week-old Moluccan Cockatoo presented for evaluation of a valgus deformity of the left tibiotarsus. The deformity had first been noticed at one week of age. The defect was managed conservatively by placing the bird in a vertical controlled position supported by rolled towels positioned around the leg. Physical therapy was performed on the leg for ten minutes at each feeding. The bird was presented at seven weeks of age for a corrective dome osteotomy (see Chapter 42).

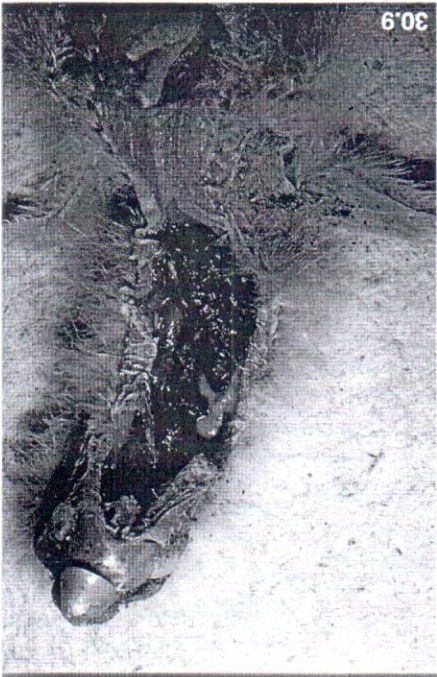
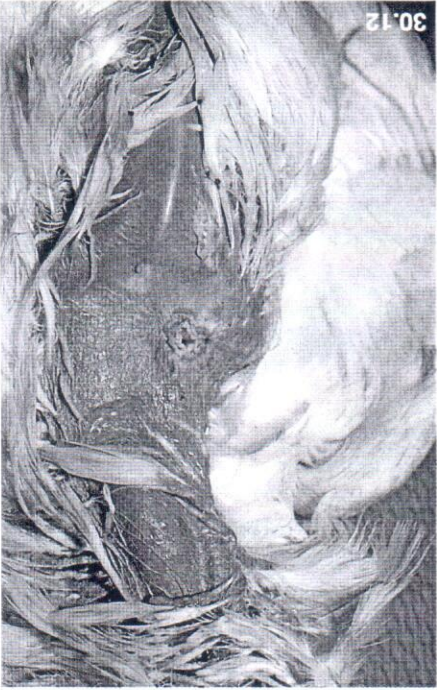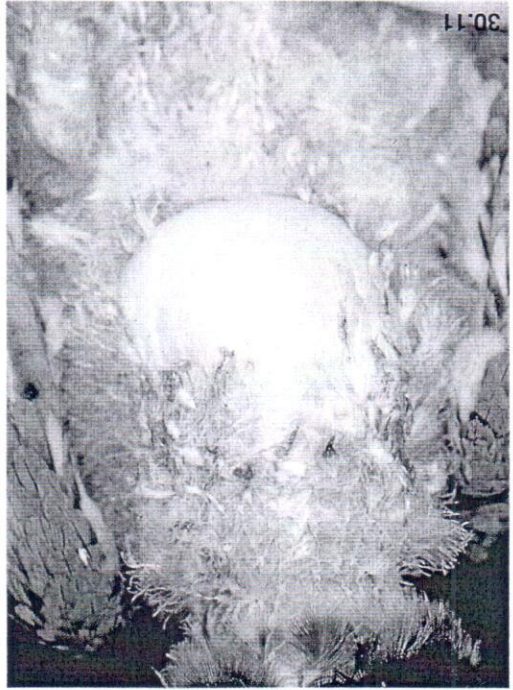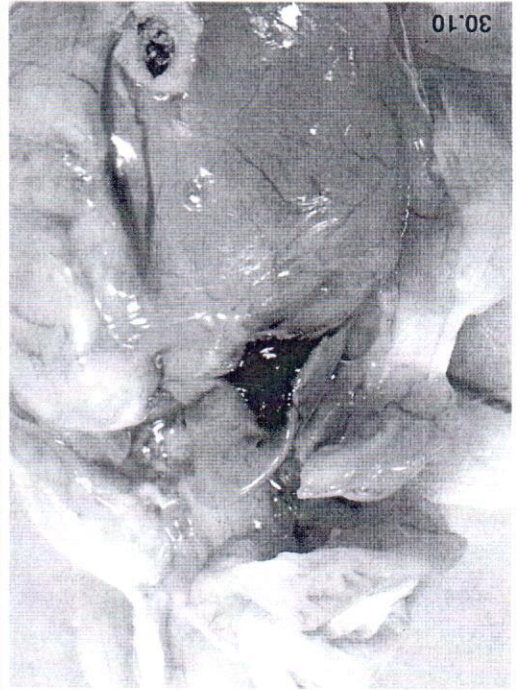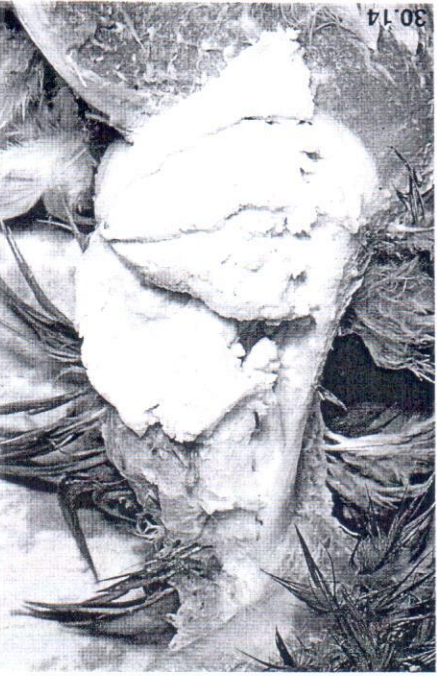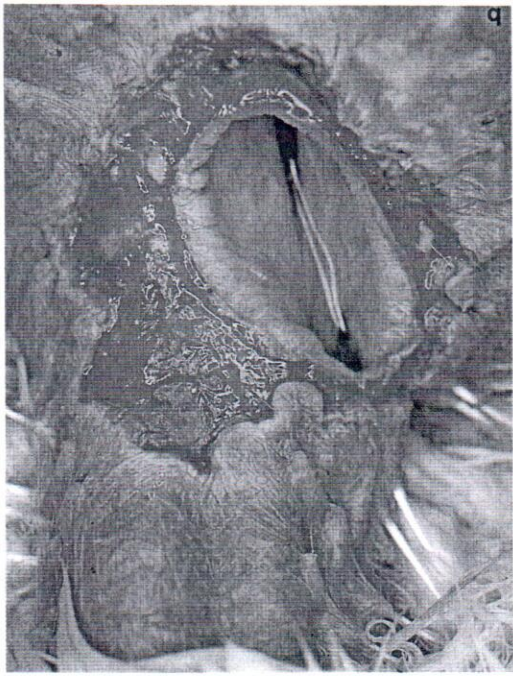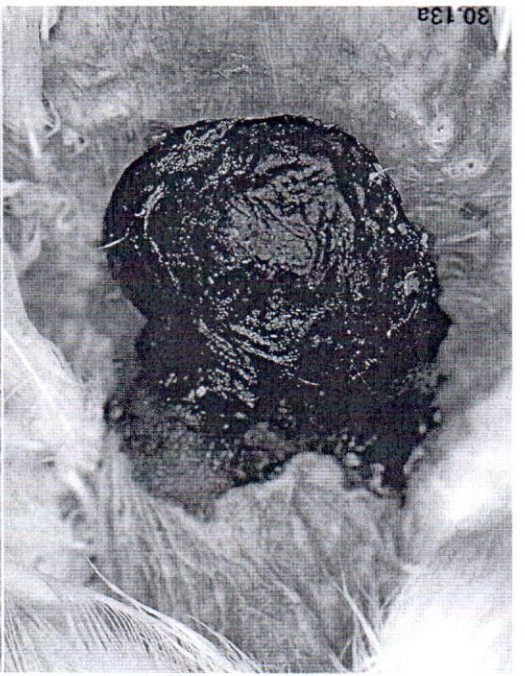### Color 30.7

A three-week-old Eclectus Parrot was presented for swelling of the distal phalanx of several digits. Numerous constrictions were present in the affected digits. Examination of the constrictions with a dissecting microscope failed to demonstrate the presence of constrictive fibers. The defects were repaired surgically and brooder humidity was increased (see Chapter 41).











## ■ Neonatology

### Color 30.8

A feeding tube or syringe tip can penetrate the pharyngeal or esophageal wall if a neonate has an over-zealous feeding response or if the feeder has a rough, careless feeding technique. Once the wall has been penetrated, food will be deposited in the subcutaneous tissues causing severe cellulitis. These cases are difficult to treat, but some birds can be saved by early and aggressive therapy that includes surgical debridement, flushing of the involved tissues and systemic antimicrobial therapy. In this photograph, a feeding tube has been placed in the esophagus to demonstrate the location of the periesophageal food.

### Color 30.9

A neonatal cockatoo was presented for necropsy after being found dead in the nest several days after hatch. This was the parents' first clutch of eggs. The parents had a broad assortment of soft foods available, including soaked monkey biscuit and mixed vegetables. The baby died from an esophageal and ingluvial impaction after being fed pieces of wood chips and dirt from the substrate in the nest box.

### Color 30.10

A 1.5-day-old Umbrella Cockatoo chick died suddenly after failing to thrive (poor feeding response, lethargic). The yolk sac had not started to absorb. The umbilicus was dry and considered to be normal. Bile pigment accumulations were noted on the dorsal surface of the liver. Aerobic and anaerobic cultures of the yolk sac revealed *Streptococcus* spp. Histopathologic findings were limited to mild hepatitis and myocarditis.

### Color 30.11

Mild crop burns may be recognized clinically as swelling, erythema and edema of the crop and esophagus.

### Color 30.12

In some cases, full-thickness crop and skin burns may cause relatively small fistulas that are easy to repair (see Chapter 41) (courtesy of Elizabeth Hillyer).

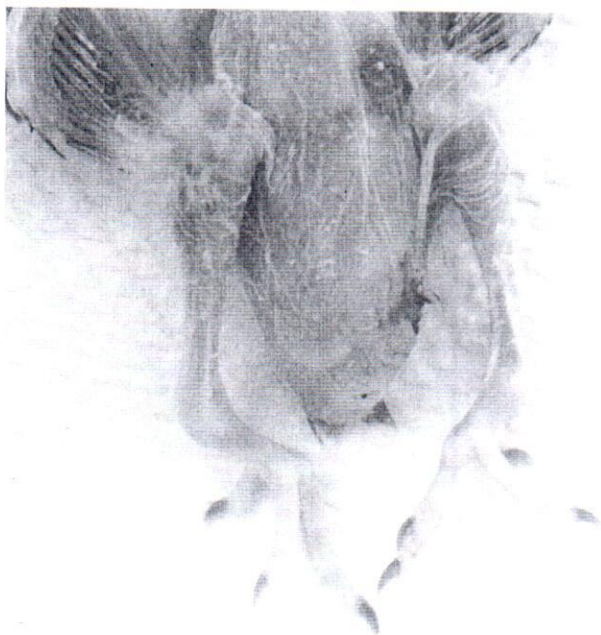### Color 30.13

Some burns can result in massive thermal necrosis of the crop and esophagus. In any crop burn, the wounds should be treated conservatively, and surgical correction should be delayed as long as possible for differentiation to occur between damaged and healthy tissue. **a)** In this case the aviculturist noted a hyperemic area in the skin over most of the crop in a six-week-old Umbrella Cockatoo. The bird was placed on smaller feedings provided more frequently to decrease crop stretching. A large scab formed over the crop and caudal esophagus over a ten-day to two-week period. Food began to leak from the caudal-most edge of the scab. The bird's overall condition was excellent, and weight gain had continued normally since the burn had first been noticed. **b)** The scab was removed, revealing the extent of the damage. A healthy bed of granulation tissue was available to facilitate repair. The wound was thoroughly cleansed and the crop was bluntly separated from the skin. The crop and skin were closed in separate layers as described in Chapter 41.

### Color 30.14

An eight-week-old Amazon chick was presented for regurgitation, weight loss and anorexia of four days' duration. The chick was the most affected of a group of 12 psittacine neonates that were having varied clinical problems associated with poor weight gain and failure to thrive. Cytologic evaluation of crop samples indicated numerous (30/HPF) budding yeast and gram-negative bacteria (40%). Abnormal clinicopathologic findings included PCV=20, WBC=4000 (numerous toxic heterophils) and TP=2.2. The crop was distended with a doughy, solid mass. The bird died shortly after presentation despite extensive supportive care. Histopathology revealed diffuse gastrointestinal candidiasis and gram-negative bacterial septicemia. The neonates in this nursery were fed from a single syringe with a single food supply that was mixed in the morning and maintained in the refrigerator between feedings.





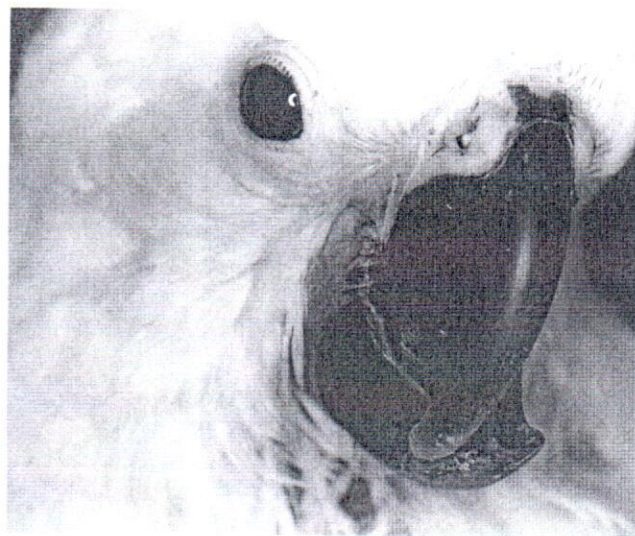**FIG 30.26** Idiopathic stifle luxation appears to be common in some species of smaller psittacine birds, especially cockatiels. The problem may be congenital, and therapy is usually ineffective (courtesy of Louise Bauck).

and permit limited, but less painful ambulation. The knee should be fixed in a slightly flexed position. Tolerance of the device is variable and it should be left in place for 30-40 days in large birds and 21 days in smaller species. Flunixin can be used for one to three days after placement and removal of the fixation device to reduce pain and inflammation.

## ■ Beak Problems

### Beak Trauma

Chicks may damage their own or a sibling's beak when they lock beaks and pump against each other, or if they pump against the brooder container.<sup>15</sup> Perlingual wounds are common and should be cleaned daily with a cotton-tipped applicator. Topical amphotericin B cream can be applied if a secondary yeast infection occurs, and antibiotics can be used to control bacterial infections. Occasionally the beak itself is damaged, creating an indentation through the beak wall. The wound should be debrided, flushed with saline, dried, and then filled with a dental acrylic. If the damaged portion of the beak is indented, it should be elevated to the level of the rest of the beak with a bent needle before applying the acrylic patch. The acrylic patch will eventually loosen as granulation tissue fills the wound. Damage and fractures of the tip of the maxillary beak should be



**FIG 30.27** A ten-week-old Umbrella Cockatoo was presented for lateral deviation of the upper beak. This defect is best corrected early when physical therapy or beak trimming procedures can be effective in resolving the problem. In older birds, like this chick, surgical techniques or implants are necessary to correct the defect (see Chapter 42).

repaired by applying dental acrylic with or without small pins to stabilize the beak tip. If the germinative center at the base of the beak is damaged, the tip will not regrow and the defect will be permanent. Birds with this condition will require frequent beak trims as the mandibular beak will continue to grow upward.<sup>15</sup>

### Lateral Beak Deviation (Scissors Beak)

Lateral deviation of the upper beak is most often diagnosed in macaws but also occurs in other psittacine birds (Figure 30.27). In most cases, it does not interfere with eating, but it is unsightly. The etiology is unknown and may be multifactorial. Suggested causes include low or unbalanced calcium in the diet, viral diseases, trauma, abnormal pressure applied by the aviculturist during hand-feeding, incubation problems and alterations in the mandibular occlusal surface.

Early recognition is critical for easy and successful correction. If noted early (ie, a few days after hatch), the lower beak should be trimmed in a ramp-like fashion to encourage the upper beak to slide over to the side opposite the curvature. Differences in the height of the occlusal surfaces of the mandibular beak should be corrected, and digital pressure should be applied to the beak two to four times daily to gently push the beak back in position. If the beak is calcified or if conservative therapy fails, a ramp built



from dental acrylic over a stainless steel mesh can be attached to the lower beak to apply pressure to correct the upper beak<sup>7</sup> (see Chapter 42). The acrylic device should be left in place for one to twelve weeks, depending on the bird's age and the severity of the defect. Correction of severe beak deformities in older birds is seldom complete, but substantial improvement can be made.

### Mandibular Prognathism

Mandibular prognathism (underbite), in which the upper beak tucks within the lower, is seen primarily in cockatoos (Figure 30.28). Severe prognathism can interfere with self-feeding. The etiology of this condition is unknown. It has been suggested that the parent bird may hook the maxilla during feeding and help extend it, an event that may not occur during hand-feeding.<sup>15</sup> Contraction of cartilaginous extensions of the beak tip may also contribute to the underbite. If the beak is still soft, physical therapy may correct the condition. A finger or loop of gauze can be used at each feeding to apply traction and extend the maxillary beak rostrally. The cartilaginous extensions should be clipped if they are contracted. If the beak is calcified, physical therapy combined with trimming of the lower beak to allow the upper to extend into a notch may help. If this fails, a dental acrylic prosthesis can be applied to the rostral end of the maxillary beak to stretch the maxilla and force it

over the mandibular beak<sup>22</sup> (see Chapter 42). The prosthesis can be removed once normal occlusion is achieved.

### Compression Deformities of the Mandible of Macaw Beaks

An elongated, shovel-like deformity of the mandible may occur in macaws when the hand-feeder compresses the lateral sides of the lower beak by holding it during feeding or cleaning. If noted before the beak calcifies, it can be corrected by trimming beak tissue from the lateral walls and manually reshaping the lower beak. Once the beak calcifies, it is difficult to repair.

### Traumatic Subluxation of the Premaxilla-frontal Joint

Juvenile birds will occasionally subluxate the upper beak when playing or flying. The upper beak will usually be displaced dorsally, and fractures of the premaxilla or frontal bone may be apparent. It is extremely painful, and the bird should be anesthetized while the beak is placed back in a normal position (see Chapter 42). Most birds have been reported to heal well, although some may need to be hand fed for a few days.<sup>8</sup> Antibiotics and anti-inflammatory drugs should be used where indicated.

## Integumentary Problems

### Feather Stress Bars

Stress bars are horizontal defects in the feathers that occur when there is endogenous release of corticosteroids or when corticosteroids are administered during feather growth (see Chapter 24). A few stress bars in an otherwise normal bird are of only temporary cosmetic concern. Large numbers of stress bars may indicate malnutrition, stunting or a disease problem. Determining the cause of stress bars is often difficult because they represent a problem that occurred when the feather was developing.

### Feather Dysplasia

Malformed feathers, feathers that fail to grow, and feathers that are easily epilated are most often caused by polyomavirus or PBFD virus. Hyperthermia, drug reactions and bacterial folliculitis are less common causes.

### Occluded Ear Openings

Occlusions of the external openings of the ears are most often seen in macaws, (especially Military Macaws). Macaws are born with a thin membrane covering the ear canal that should start to open between



**FIG 30.28** A three-week-old Umbrella Cockatoo was presented with severe mandibular prognathism. The problem had been present since hatching, and the aviculturist had been incorrectly told that this was normal and would resolve with age. If corrected from hatching, this problem can be resolved by gently pulling the upper beak forward and placing it over the lower beak for about ten minutes between each feeding. If allowed to progress, as in this cockatoo, repair requires surgical intervention (see Chapter 42).





**FIG 30.29** A four-week-old Green-winged Macaw was presented for depression and failure to grow. The bird was being fed a homemade diet with a baby cereal base that was nutritionally deficient. The bird grew normally when placed on a commercial hand-feeding formula. Note the membrane over the ear that has not yet opened.

12 and 35 days of age (Figure 30.29). If the canal fails to open, it should be explored with blunt forceps and an opening surgically created if necessary. If a small hole is found, it can often be enlarged by stretching it with the tips of a pair of hemostats. Occasionally the

canal will become infected and fill with inspissated pus. This material should be removed by curette and flushing, cultured for bacteria and fungus, and the ear treated with appropriate topical and systemic antibiotics. *Pseudomonas* sp. is a common contaminant and ointments containing an aminoglycoside antibiotic should be used until culture results are available.

### Eyelid Malformation

Malformation of the eyelids resulting in a narrow aperture is occasionally seen in cockatiels. Several surgical techniques and means of chemical debridement have been attempted with little success.<sup>5</sup> In reported cases, the aperture closed following treatment. Affected birds can often adapt to this handicap (see Chapter 26).

### References and Suggested Reading

- Altman RB: Disorders of the skeletal system. In Petrak ML (ed): *Diseases of Cage and Aviary Birds* 2nd ed. Philadelphia, Lea and Febiger, 1982, pp 382-394.
- Arnall L: Anesthesia and surgery in cage and aviary birds III. A systematic outline of surgical conditions. *Vet Rec* 73:188-192, 1961.
- Beach JE: Diseases of budgerigars and other cage birds, a survey of post-mortem findings. *Vet Rec* 74:134-140, 1962.
- Bond MW: Avian pediatrics. *Proc Assoc Avian Vet*, Chicago, 1991, pp 153-160.
- Buyukmihci NC, et al: Eyelid malformation in four cockatiels. *J Am Vet Med Assoc* 196(9):1490-1492, 1990.
- Cambre RC: Indications and technique for surgical removal of the avian yolk sac. *J Zoo Wildlife Med* 23:55-61, 1992.
- Clipsham R: Correction of pediatric leg disorders. *Proc Assoc Avian Vet*, 1991, pp 200-204.
- Clipsham R: Introduction to psittacine pediatrics. *Vet Clin No Am Sm Anim Pract* 21:1361-1392, 1991.
- Clubb K, Clubb S: Management of psittacine chicks and eggs in the nest. In Schubot RM, Clubb K, Clubb SL: *Psittacine Aviculture. Perspectives, Techniques and Research*. Loxahatchee, Avicultural Breeding and Research Center, 1992, pp 15/1-15/6.
- Clubb K, Clubb S: Psittacine neonatal care and handfeeding. In Schubot RM, Clubb K, Clubb SL: *Psittacine Aviculture. Perspectives, Techniques and Research*. Loxahatchee, Avicultural Breeding and Research Center, 1992, pp 11/1-11/12.
- Clubb K, et al: Growth rates of hand-fed psittacine chicks. In Schubot RM, Clubb K, Clubb SL: *Psittacine Aviculture. Perspectives, Techniques and Research*. Loxahatchee, Avicultural Breeding and Research Center, 1992, pp 14/1-14/19.
- Clubb SL, et al: Hematological and serum biochemical reference intervals in juvenile Eclectus parrots (*Eclectus roratus*). *J Assoc Avian Vet* 4:218-225, 1991.
- Clubb SL, et al: Hematological and serum biochemical reference intervals in juvenile cockatoos. *J Assoc Avian Vet* 5:5-16, 1991.
- Clubb SL, et al: Hematological and serum biochemical reference intervals in juvenile macaws. *J Assoc Avian Vet* 5:154-162, 1991.
- Clubb SL, Wolf S, Phillips A: Psittacine pediatric medicine. In Schubot RM, Clubb K, Clubb SL: *Psittacine Aviculture. Perspectives, Techniques and Research*. Loxahatchee, Avicultural Breeding and Research Center, 1992, pp 16/1-16/26.
- Drewes LA, Flammer K: Preliminary data on aerobic microflora of baby psittacine birds. *Proc Jean Delacour/International Foundation for Conservation of Birds, Intl Symp Breed Birds in Captivity*, 1983, pp 73-81.
- Flammer K, Drewes LA: Environmental sources of gram-negative bacteria in an exotic bird farm. *Proc Jean Delacour/Intl Foundation for the Conservation of Birds, Intl Symp Breed Birds in Captivity*, 1983, pp 83-93.
- Flammer K: Pediatric medicine. In Harrison GJ, Harrison LR (eds): *Clinical Avian Medicine and Surgery*. Philadelphia, WB Saunders Co, 1986, pp 634-650.
- Gaskin JM, Horner BL, Eskelund KH: Preliminary findings in avian viral serositis: A newly recognized syndrome of psittacine birds. *J Assoc Avian Vet* 5:27-33, 1991.
- Greenacre CB, Watson E, Ritchie BW: Congenital atresia of the choanae in an African grey parrot and an umbrella cockatoo. *J Assoc Avian Vet* 7:19-22, 1993.
- Hanson JT: Handraising large parrots: Methodology and expected weight gains. *Zoo Biol* 6:139-160, 1987.
- Joyner KL, Abbott U: Egg necropsy technique. *Proc Assoc Avian Vet*, 1991, pp 146-152.
- Joyner KL: Psittacine pediatric diagnostics. *Sem Avian and Exotic Pet Medicine* 1:11-21, 1992.
- Karpinski LG, Clubb SL: Further investigations into the ocular problems of caged birds. *Proc Assoc Avian Vet*, Boulder, 1985, pp 101-108.
- Lyman R: Neurological disorders. In Harrison GJ, Harrison LR (eds): *Clinical Avian Medicine and Surgery*. Philadelphia, WB Saunders, 1986, pp 486-490.
- Opengart KN, et al: Congenital ex hepatic biliary cyst in a congo African grey parrot (*Psittacus erithacus erithacus*). *Avian Dis* 34:497-500, 1990.
- Phillips A, Clubb SL: Psittacine neonatal development. In Schubot RM, Clubb K, Clubb SL: *Psittacine Aviculture. Perspectives, Techniques and Research*. Loxahatchee, Avicultural Breeding and Research Center, 1992, pp 12/1-12/26.
- Ritchie BW, et al: Avian polyomavirus: An overview. *J Assoc Avian Vet* 5:147-153, 1991.
- Ritchie BW, et al: Advances in understanding the PBFD virus. *Proc Assoc Avian Vet* 1990, 12-24.
- Roudybush TE: Growth, signs of deficiency, and weaning in cockatiels deficient diets. *Proc Assoc Avian Vet* 1986, pp 333-340.
- Roudybush TE, Grau CR: Solids in diets for hand raising cockatiels. 32nd West Poult Dis Conf, 1983, p 94-95.
- Small E, Burke TJ: Diseases of the organs of special sense. In Petrak M (ed): *Diseases of Cage and Aviary Birds* 2nd ed. Philadelphia, Lea and Febiger, 1982, pp 491-496.
- Takeshita K: Hypervitaminosis D in baby macaws. *Proc Assoc Avian Vet* 1986, pp 341-346.
- Pediatrics: Part 1. Seminars in Avian and Exotic Pet Medicine. 1(1), 1992.
- VanDerHeyden N: Jejunostomy and jejunocecal anastomosis in macaws. *Proc Assoc Avian Vet* 1993, 72-77.